

Case Report

BASAL CELL CARCINOMA IN DOGS- A REPORT OF 2 CASES

**P Ravi Kumar¹, B Sailaja¹, V Devi Prasad², P Sudharani Chowdary⁴ and
Makkena Sreenu³**

¹Assistant professor, Department of Veterinary Surgery and Radiology,

²Associate professor, Department of Veterinary Surgery and Radiology,

³Professor & Head, Department of Veterinary Surgery and Radiology,

⁴Assistant Professor, Department of TVCC,

NTR College of Veterinary Science, Gannavaram- 521 102 (AP)

E-mail: ravikumarpallitvm1018@gmail.com (*Corresponding Author)

Abstract: Tumor mass on ventral aspect of neck and other with a tumor mass on dorsal aspect of head were tentatively diagnosed as basal cell carcinoma by fine needle aspiration cytology and were later confirmed by histopathology. Surgical excision was performed under general anesthesia in both the animals which improved the well being of the animals. The clinical findings, diagnosis and surgical management of the condition, outcome of the cases were discussed.

Keywords: Basal cell carcinoma, malignancy, metastasis, ulceration, surgical excision.

Introduction

Basal cell carcinoma is a malignant epithelial tumor of the skin which is entirely composed of basal cells and frequently seen in cats than in dogs and rare in other domestic animals (Goldschmidt *et al.*, 1998). Basal cell tumors grow slowly and steadily invading the neighboring tissues but the chance of metastasis is very less (Ahmmed et al., 2014). In dogs the usual location is head and neck where it is majorly exposed to sun light (Goldschmidt and Hendrick, 2002). Invasion of tumor cells to surrounding tissues depends on their location as tumor cells at thorax, head and neck usually invade to surrounding tissue while at the other parts these cells cannot invade (Walder and Gross, 1992). These tumors often appear as ulcerated masses over the extremities like head and neck (Villalaobos, 2014). Reports were available suggesting the occurrence of these tumors in different species like buffaloes (Sadana *et al.*, 1978), dog (Roberts *et al.*, 1986) cats (Jorger, 1988) etc. In the present paper, the diagnosis and the surgical management of basal cell carcinoma in two dogs were reported.

Case history and Observations

Two male dogs were presented to clinics with presence of progressively growing ulcerated masses which were existing for a long period, with symptoms of anorexia, emaciation, and bleeding from the tumour. Findings of clinical examination revealed that, the masses were ulcerated and hard in consistency and regional lymph nodes were found swollen.

In case 1, a male German shepherd with six years of age showed swelling on the Ventral aspect of neck for a period of 12 months (Fig-1) and in case 2, a male Pomeranian with eight years of age showed swelling on the Dorsal aspect of Head for a period of 5 months (Fig-2). Lateral thoracic radiographs disclosed nodular pattern (Fig-3) in the lung lobes suggesting metastasis in both the animals. Hematological parameters showed moderate anemia and neutrophilia. Serum biochemical parameters showed elevated blood urea nitrogen and creatinine levels. Based on the fine needle aspiration cytology, these masses were tentatively diagnosed as basal cell carcinomas which were later confirmed by histopathology.

Treatment

Elective surgery was planned at later date in both the cases and they were given hematonics besides supportive drugs to improve the condition of the animals, so as to withstand anesthesia and surgery. On the day of surgery, both the animals were premedicated with atropine sulphate at the dose rate of 0.04 mg/Kg Body weight subcutaneously; anaesthesia was induced with Ketamine hydrochloride at the dose rate of 5mg/Kg body weight and Diazepam at the dose rate of 0.5 mg /Kg body weight intravenously and was maintained with Isoflurane. An elliptical skin incision was made around the tumor in both the cases and the tumour was carefully excised from the underlying tissues by blunt dissection procedures to avoid trauma. The tissue planes and cutaneous edges were sutured as per the standard procedure and a piece of excised tumor mass was sent for histopathology which revealed proliferating basal cells with palisading arrangement of nuclei (Fig-4) which confirmed basal cell carcinoma.

Postoperatively, the dog was given intra muscular injections of ceftriaxone sodium at the dose rate of 25 mg per Kg body weight for 7 days, Meloxicam at the dose rate of 0.2 mg per Kg body weight for 3 days and supportive therapy with multivitamin tonics orally for 15 days and hematonics orally for 30 days.

Results and Discussion

The condition of the animals appeared to be improved in both the animals and normal feeding habits were resumed after surgery. In case 1, by the end of eight month postoperatively, the

condition of the animal started deteriorating. It was brought to the clinics again, with complaints of alopecia, inappetance, anemia, moderate dehydration, moderate expiratory dyspnoea etc. Lateral chest radiograph revealed exaggerated metastatic foci occupying much of the lung parenchyma. It was treated with oxygen through face mask, fluid therapy with isotonic crystalloid solutions, plasma expanders, broad spectrum antibiotics etc. with no encouraging results and death had taken place after a few days. Postmortem examination revealed several nodular lesions in the lung lobes (Fig-5) suggesting severe metastasis in that case while, no recurrence was observed in case 2 during an observation period of one year.

In the present study, tumors were noticed in middle aged dogs which appear to deviate from the statement of Villalaobos, (2014), who postulated that, basal cell carcinomas were usually seen in aged dogs. The location of tumors i.e. neck and head is in concurrence with the findings of Golschmidt and Hendrick, (2002) who asserted that, basal cell carcinomas usually occurred at head and neck region. The etiology of tumor in the present case was exactly unknown but it could be attributed to solar damage based on the location of tumor as well as the history of the animals that, they usually leave the dogs outside the house in small kennels where there is no proper shade. Saridomichelakis *et al.* (2013) reported that, exposure of skin to excess sun light might cause basal cell carcinomas. However, Walder and Gross, (1992) observed basal cell carcinomas in cats at non sun exposed locations of the body. Hence further research is needed in identifying the exact predisposing factor for the development of this type of tumors in dogs and cats.

The clinical signs exhibited by the animal, the morphology and texture of the tumor mass in both the cases forced the authors to suspect for epithelial tumors of skin and the fine needle aspiration cytology strengthened the suspicion. Later this was confirmed as basal cell carcinoma by histopathology of the tumor mass. Metastasis was observed in both animals which was stated as a rare occurrence in basal cell carcinoma by Villalaobos, (2014), whereas Goldschmidt *et al.*,(1998) opined that basal carcinomas are locally invasive but in few cases they may metastasize and recur. Surgical excision of the tumor mass was planned in the present study after stabilization of condition of animal, which was stated as a better choice of treatment for basal cell carcinoma in dogs by Villalaobos, (2014). Surgery in case 1 could increase the longevity of the animal by another 8 months but unable to prevent its death severe metastasis. No recurrence was noticed in case 2, which was attributed to its early presentation when compared to case 1.

Conclusion

Basal cell carcinoma which is a malignant tumor of skin can easily be diagnosed based on the clinical signs exhibited by the animal and histopathology of the tumor mass. These tumors can affectively managed by surgical resection but the delayed presentation may get some bitter experiences inspite of good treatment. Hence the owners should be educated about this type of tumor so as to facilitate early diagnosis and treatment

References

- [1] Ahamad DB, Azmi S, Sood S, Sivaseelan S and Puvarajan B (2104). Cytological and Pathomorphological Studies on Basal Cell Carcinoma in Skin of New Zealand White Rabbit. *Shanlax International Journal of Veterinary Science*. Vol.1 No.4 July-Sep 2014.
- [2] Goldschmidt, M.H, Dunstan, R.W., Stannard, A.A., von Tscharner, C., Walder, E.J. and Yager, J.A. (1998). Histological classification of epithelial and melanocytic tumors of the skin of domestic animals. WHO Bulletin. 2nd edn. Vol. III, *Armed Forces Institute of Pathology, Washington*. 15-106.
- [3] Goldschmidt, M.H. and Hendrick, M.J. (2002). Tumors of the skin and soft Tissues. In: *Tumors in Domestic Animals. 4th edn. D.J. Meuten (eds.), Ames, Iowa, Iowa State University Press*. 45-117.
- [4] Jorger, K.(1988). Skin tumours in cats. Occurrence and prevalence in specimens (biopsies 1984-1987) at the Zurich Institute of Veterinary Pathology. *Schweizer Archiv fur Tierheilkunde*. 130(10): 559-569
- [5] Roberts, S.M, Severin, G.A, Lavach, J.D. (1986). Prevalence and treatment of palpebral neoplasms in the dog: 200 cases (1975-1983). *J American Vet. MedAssoc*. 189(10): 1355-1359.
- [6] Sadana, JR, Mahajan, S K, Kumar, VR.(1978). A note on basal cell carcinoma in a buffalo. *Indian J. Animal Sci*. 48(9): 684-685
- [7] Saridomichelakis, M.N., Day, M.Y., Apostolidis, K.N., Tsioli, V., Athanasiov, L.V. and Koutinas, A.F. (2013) Basal cell carcinoma in a dog with chronic solar dermatitis. *J. Small Anim. Pract.*, 54 (2):108-111.
- [8] Villalabos AE, (2014). Tumors of the skin and soft tissues. In: *The Merck's Veterinary Manual 10th Edition*, p 859-860.
- [9] Walder EJ and Gross TL. (1992). Basal cell tumor. In: *Veterinary Dermatopathology*. T.L Gross, P.J. Ihrke and E.J. Walder (edn.), Missouri, Mosby Year Book, Inc. 343-350.

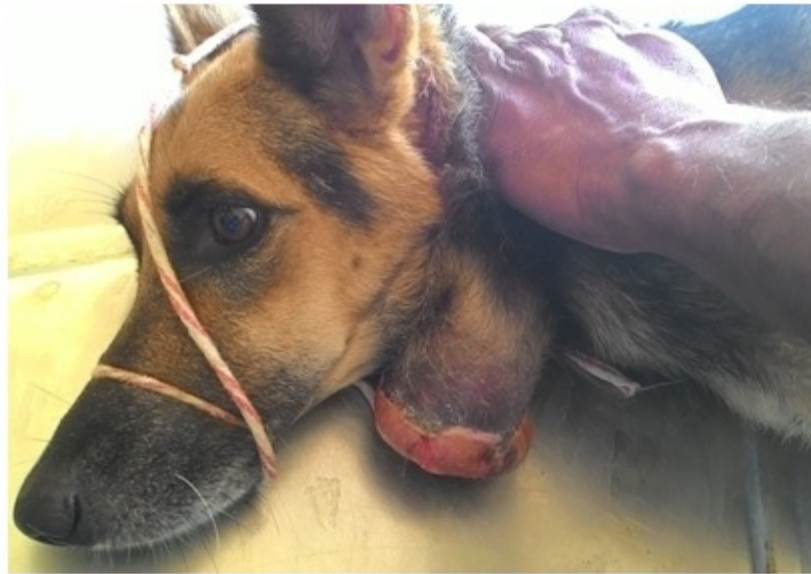

Fig-1: Photo showing an ulcerated mass on ventral aspect of neck in a German shepherd dog

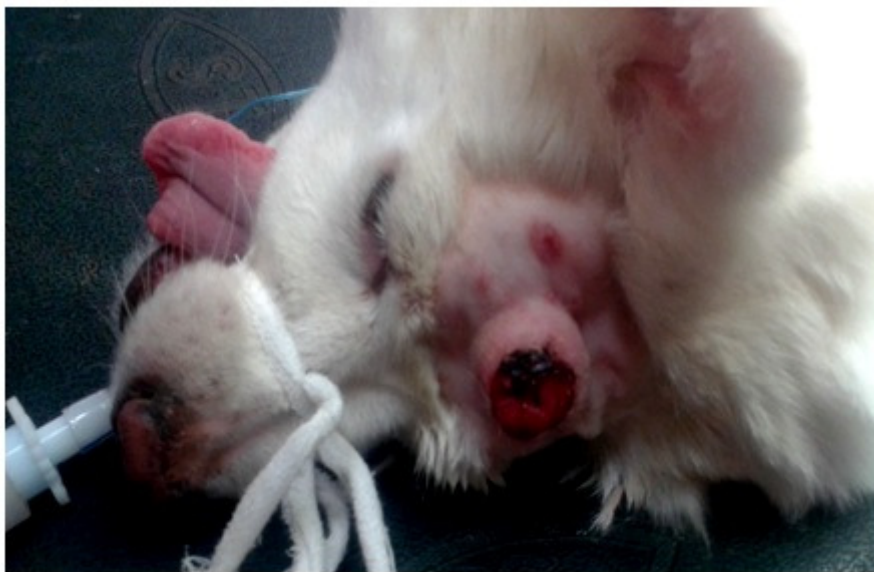

Fig-2: Photo showing an ulcerated mass on dorsal aspect of skull in a Pomeranian dog

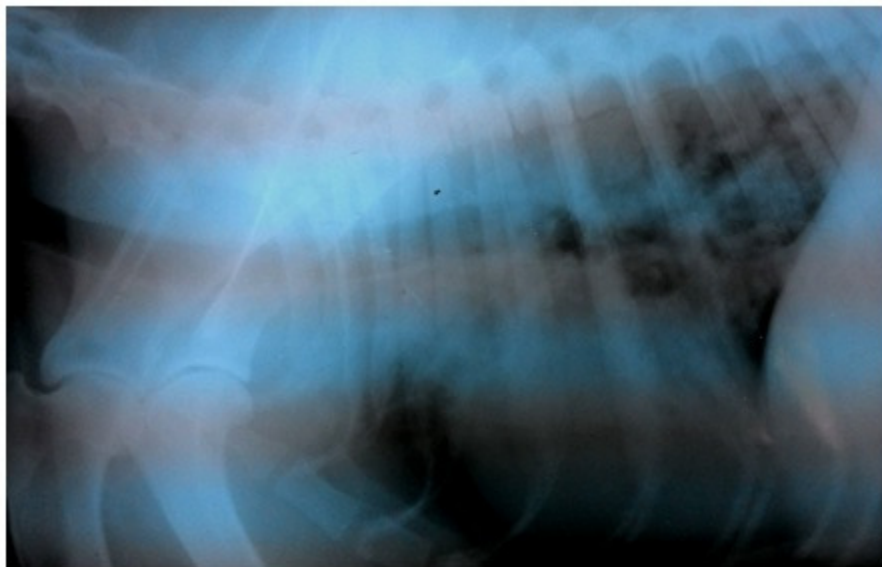


Fig-3: Radiograph of Lateral thorax showing nodules in lung parenchyma in a German shepherd dog

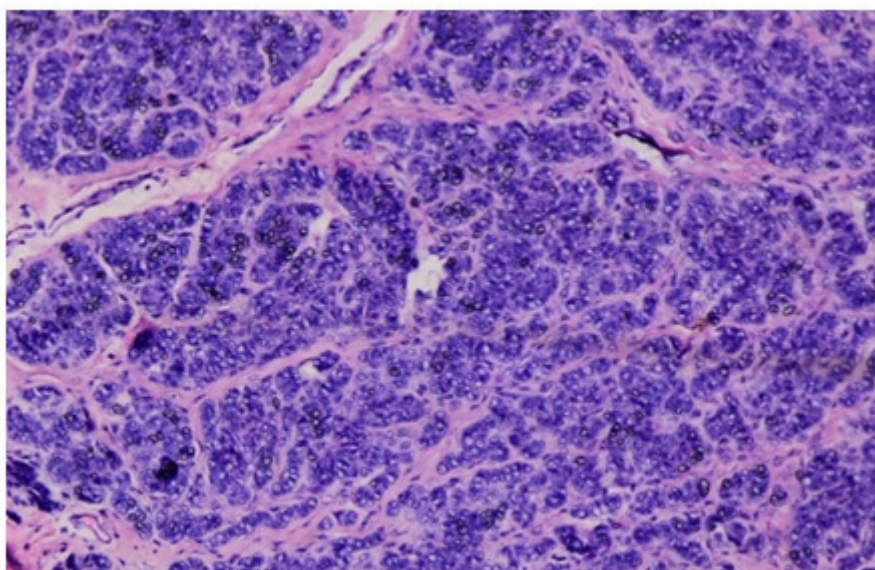


Fig-4: Micro photograph showing proliferating basal cells with palisading arrangement of nuclei. H&E, 100X

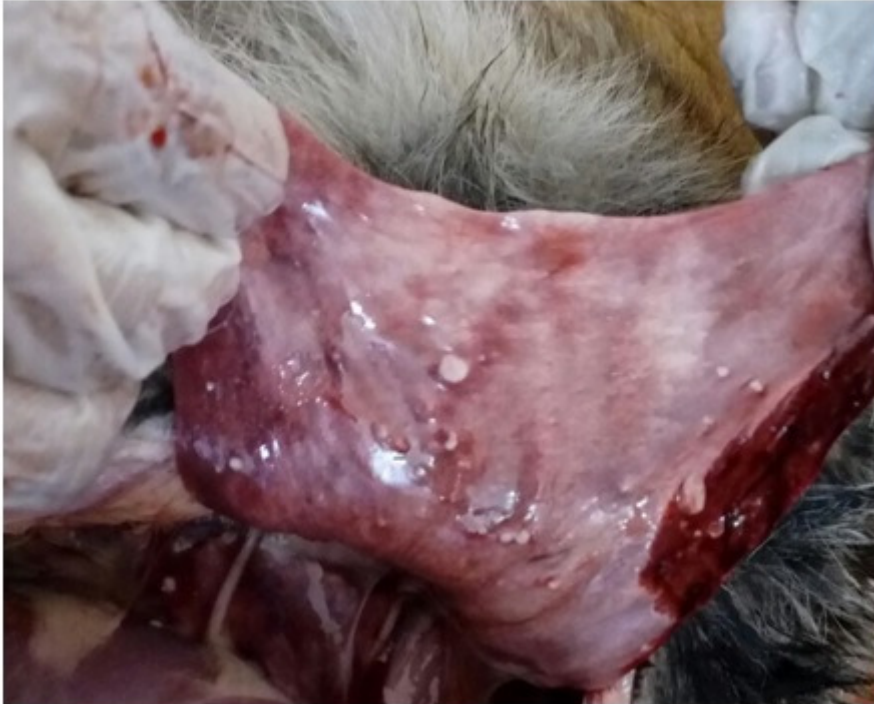

Fig-5: Photograph showing multiple nodules on the lung in a German shepherd dog during autopsy