

MORPHOLOGICAL & HISTOLOGICAL STUDY ON GALL BLADDER OF MARWARI GOAT

¹Mahesh Bamaniya*, ²Yogesh Barolia, ³Rakesh Mathur, ⁴Kavita Shende
and ⁵Sanjeev Joshi,

¹Veterinary Officer, ² Project Associate, ³Professor, ⁴Assistant Professor,

⁵Professor & Head College of Veterinary and Animal Science, Bikaner

RAJUVAS, Bikaner, (Rajasthan -334001), INDIA

E-mail: maheshbamaniyaakki@gmail.com (*Corresponding Author)

Abstract: Present study was conducted on the Gall Bladder of 50 adult Marwari goats. Gall bladder is situated at the level of ninth rib. It lies partly in the gall bladder fossa of the liver to which it was adhered and partly remained in contact with the abdominal wall. In the Marwari goat the gall bladder was observed as a pear shaped sac, yellowish-white in colour, which remained filled with green coloured bile juice. Histology of Gall bladder revealed that it was lined by tall columnar ciliated epithelium.

Keywords: Marwari Goat, Gall bladder, Liver, Bile juice.

Introduction

Marwari goat (*Capra hircus*) is a domestic animal distributed in the Marwar region of Rajasthan (<http://www.fao.org>). The goat is one of the most important animal and the goat husbandry has been playing an important role in the economy of our country with special reference to milk, meat, manure and hide production (Arora *et al.*, 2013).

In the developing countries, a number of large and small farmers rear goat for their livelihood (Singh *et al.*, 2006). It is known as the 'poor man's cow' in India and as 'wet nurse' of infants in Europe (Iqbal *et al.*, 2008). Research on this species has been largely neglected (Bhattarai, 2012), especially its anatomy. So the detailed study of the different aspects of goat anatomy is required. Selection of the species is based on the local inhabitance and meager availability of literature on this quadruped.

The present study is an investigation into the histology of the gall bladder of goat to add the knowledge in this field. It is also hoped that the present results help to elucidate the structure of this organ.

Materials and Methods

The present study was conducted on fifty apparently healthy adult Marwari Goat (*Capra hircus*) of either sex. About 50 gall bladders were collected from the freshly slaughtered

goats at Municipal slaughter house, Bikaner for morphological study. Out of them 15 gall bladders were taken for histological studies. The samples were taken immediately as soon as possible from the gall bladder. The samples were put in the 10% neutral buffered formalin (Gridley, 1960; Sheehan and Hrapchak, 1987; Carson, 1997).

From each gall bladder, the tissues were collected from thirteen fixed anatomical regions to explore regional differences if any. The tissues were preserved in 10% formal saline for 48 hrs, Bouin's fluid for 12 hrs, and Zenker's fluid for 18 hrs. Fixed tissue was latter washed in running tap water for 6-10 hours followed by dehydration in ascending grade of alcohol, clearing, embedding in paraffin wax of melting point of 58-60 °C, preparation of blocks, section cutting (5-6 µm thick), and mounting of section on albuminized slides, drying of sections and finally stained with the following routine histological stains to demonstrate the components of gall bladder.

1. Earlich's Haematoxylin and Eosin stain for routine observation (Singh and Sulochana 1997).
2. Gomori's method for reticulum (Luna, 1968).
3. Silver impregnation for reticular, elastic and collagen fibres (Culling C.F.A., 1974)
4. Verhoeff's elastic stain for elastic and collagen fibres (Singh and Sulochana 1997).
5. Van Gieson stain for collagen fibres. (Singh and Sulochana 1997).
6. Masson's trichrome method for collagen fibres (Singh and Sulochana 1997).
7. Periodic Acid-Schiff (PAS) reaction for glycogen (Luna, 1968).

Result and Discussion

The visceral surface of the liver was related to the reticulum, omasum, duodenum and gall bladder (Fig.1). Gall bladder lies partly in the gall bladder fossa of the liver to which it was adhered and partly remained in contact with the abdominal wall, as mentioned by May (1955) and Pareek (2000) in sheep and Modekar *et al.* (2003) in goat. It was observed in the present study that gall bladder was situated at the level of ninth rib and its caudal end was located at the eighth inter-costal space; this was similar to the observation of May (1955) and Pareek (2000) in sheep.

In the goat the gall bladder was observed as a pear shaped sac, yellowish-white in colour, which remained filled with green coloured bile juice. These findings were similar to that of Raghavan (1964), Getty (1977) and Nickel *et al.* (1979) in ruminants. Dyce *et al.* (1996) mentioned that in small ruminants the gall bladder was more elongated. Sisson and Grossman (1958) reported in horse that the gall bladder was absent and similar findings were also

reported in camel by Grossman (1960) and Smuts and Bezuidenhout (1987). Abidu-Figueiredo *et al.* (2006) also mentioned that there was no gall bladder in the ostrich.

In present study the gall bladder was lined by tall columnar ciliated epithelium with occasional goblet cells (Fig.2). Trautmann and Fiebiger (1957) and Pareek (2000) in sheep mentioned similar findings. There was no gland observed in the mucosa of gall bladder in goat. The human gall bladder is lined by a surface epithelium, composed of columnar cells which bear irregular microvilli with a glycoprotein surface coat, this make the apical surface of the cells become positive with PAS staining (Seiden, 2002). The gall bladder is storage deport for bile. Goblet cells have been also reported in the epithelium of the cow. Mucous, serous, or mixed glands are often seen in the wall of the gallbladder of ruminanats, but such goblet cells were not reported in bird generally (Hodges,1974 and Bacha and Wood, 1990).

Conclusion

It can be concluded from this study that Gall bladder of Marwari goat was situated on the visceral surface and partly lies in the gall bladder fossa of the liver at the level of ninth rib. The yellow-white coloured gall bladder of Marwari goat was pear shaped and contained green coloured bile juice. Histologically the gall bladder of this species was lined by columnar ciliated epithelium with occasional goblet cells.

References

- [1] Abidu-Figueiredo, M., Xavier, S.B., Bath, F.V.C., Babinski, M.A., and Chagas, M.A. (2006). Morphological and topographical aspects of the ostrich (*Struthio camelus*) liver. *Revista Portuguesa de Ciencias Veterinarias*. 101(557/558): 41-43.
- [2] Arora, R., Bhojak, N. and Joshi, R. (2013). Comparative aspects of goat and cow milk. *International Journal of Engineering Science Invention*. 2(1), pp: 7-10.
- [3] Bacha, W. J. and Wood, L. M. (1990). *Color atlas of veterinary histology*. Philadelphia, Lea and Febiger. William and Wilkins a Waverly Company. PP: 113-114.
- [4] Bhattarai, R.R. (2012). Importance of Goat Milk. *J. Food Sci. & Technol. Nepal*, 7(1): pp:107-111.
- [5] Carson, L.F. (1997). *Histotechnology A Self-Instructional Text*. Chicago, ASCP Press. PP: 97-140.
- [6] Culling, C.F.A. (1974). *Handbook of histochemical technique*, 3rd edⁿ, Butterworths & Co. Ltd. pp: 302.
- [7] Dyce, K.M., Sack, W.O. and Wensing, C.J.G. (1996). *The Text book of Veterinary Anatomy, II End.*, W.B. Saunder's Company, Philadelphia, pp: 651-652.

- [8] Getty, R. (1977). Sisson and Grossman's. The Anatomy of the Domestic Animals" VI. The Mcmillan Company of India Ltd. Madras, Delhi, Bombay, Calcutta V Edn. pp: 908-913.
- [9] Gridley, M.F.(1960): Manual Of Histologic and Special Staining Techniques. Second edition. New York, McGraw-Hill Book Company, INC. PP: 27-142.
- [10] Grossman, J.D. (1960). A Student's Guide to Anatomy of the Camel. Indian Council of Agricultural Research, New Delhi. pp: 44-45.
- [11] Hodges, R.D. (1974). The Histology of the Fowl. London, Academic Press, Inc.LTD. PP: 55- 101.
- [12] Iqbal, A., Khan, B.B., Tariq, M. and Mirza, M.A. (2008). Goat-A Potential Dairy Animal: Present and Future Prospects. *Pak. J. Agri. Sci.*, 45(2): 227-230.
- [13] Luna, L.G. (1968). Manual of histological staining methods of armed force institute of pathology. 3rd edⁿ. McGraw-Hill Book Company, New York. pp: 87- 88, 94-95.
- [14] May, N.D.S. (1955). The Anatomy of the Sheep with instruction for its Dissection, the University of Queensland press Brisbane, pp: 105-107.
- [15] Modekar,S.S., Bhosle, N.S., and Mamde,C.S. (2003). Morphological study of liver in Osmanabadi goat (*Capra hircus*). *Indian Journal of Veterinary Anatomy*.15(1/2): 65-67.
- [16] Nickel, R., Schumer, A. and Seiferle, E. (1979). The Anatomy of the Domestic Animals, ren. 11nd End., Verlag Paul parey, Berlin, pp: 114-119, 176-178.
- [17] Pareek, P. (2000). Gross and Histological studies of the liver in Magra Sheep (*Ovis aries*) M.V.Sc. Thesis College of Veterinary and Animal Science Rajasthan Agricultural University, Bikaner. pp: 1-78.
- [18] Raghavan, D. (1964). Anatomy Ox, 1st edn., Indian Council of Agriculture Research, New Delhi, pp: 370-374.
- [19] Seiden, D.(2002): USMLE Step 1 Anatomy notes. California, Kaplan, Inc. PP: 59-186.
- Sheehan, D.C. and Hrapchak, B.B. (1987). Theory and practice of histotechnology. 3rd ed. Columbus, Battelle Press. PP: 42-199.
- [20] Singh, S.K., Singh, M.K. and Singh, N.P. (2006). Role of goats in sustainable rural livelihoods in India. In "Goats-Undervalued Assets in Asia". Proceedings of the Aphca- Ilri Regional Workshop on Goat Production Systemsand Markets. Luang Prabang, Lao PDR, 24-25 October 2006.
- [21] Singh, U.B. and Sulochana, S.A. (1997). Handbook of histological and histochemical technique. Premier publishing house Hyderabad. Pp: 8-57.

[22] Sisson, S. and Grossman, J.D. (1958). *The Anatomy of the Domestic Animals*. rev. 1V Edn. Asia Publishing House, New Delhi: 437-442, 472-475, 482-484.

[23] Smuts, Malie, M.S. and Bezuidenhout, A.J. (1987). *Anatomy of the Dromedary*. Oxford Science Publications, Oxford, pp: 129-132.

[24] Trautmann, A. and Fiebiger, J. (1957). *Fundamentals of the Histology of Domestic Animals*. Comstock Publishing Associates Ithaca, New York, 1957. pp: 219-224.

Figures

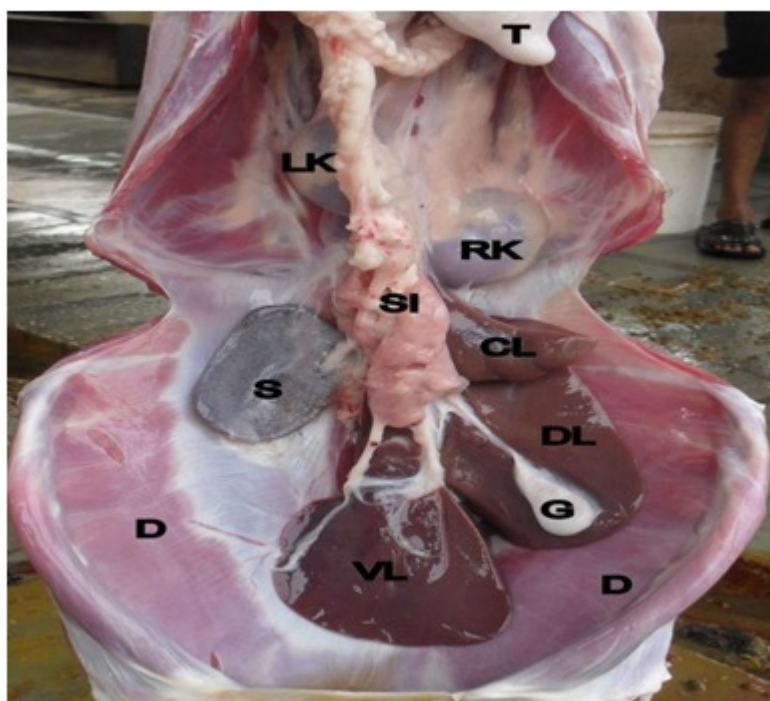


Fig.1 Gall bladder (G)

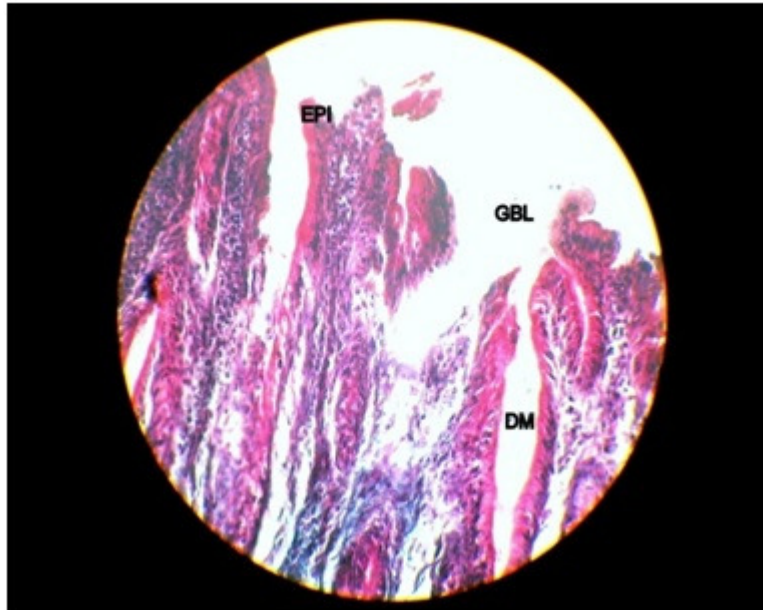


Fig. 2 Cross section of gall bladder