

FRENULOPLASTY FOR CONGENITAL ANKYLOGLOSSIA IN A CALF

P Ravi Kumar¹, V Devi Prasad², Makkena Sreenu³, D Bhagyaraju⁴ and VSC Bose⁴

¹Assistant professor, ²Associate professor, ³Professor & Head, ⁴Contract Teaching Faculty,

Department of Veterinary Surgery and Radiology,

NTR College of Veterinary science, Gannavaram- 521 102(AP)

E-mail: ravikumarpallitvm1018@gmail.com (*Corresponding Author)

Abstract: A two day old male ongole calf with an abnormality in the buccal cavity was diagnosed to have ankyloglossia. Frenuloplasty was performed to correct the condition with favorable results. By third postoperative day the calf was able to move its tongue in all directions and able to swallow the milk with no signs of regurgitation.

Keywords: Ankyloglossia, Tongue tie, Frenuloplasty, Regurgitation.

Introduction

Ankyloglossia is a congenital anomaly of oral cavity which is otherwise termed as tongue tie. It is characterized by an abnormally short lingual frenulum resulting in decreased mobility of tongue (Hernandez and Negro, 1999). Reports on ankyloglossia are available in kids (Nair and Bandopadyay, 1994); camel calves (Ramadan, 1994); puppies (Kilic and Sarierler, 2004); newborn infants (Heller *et al.*, 2005) and in calves (Rajesh *et al.*, 2010, Kilic, 2011). This condition can be treated by frenulotomy or frenuloplasty. In the present paper, repair of ankyloglossia by frenuloplasty in a male Ongole calf has been reported.

History and observations

A two day old male Ongole calf was presented to the department of Veterinary Surgery and Radiology, NTR College of Veterinary Science, Gannavaram with a complaint of regurgitation of milk during suckling along with drooling of saliva. Physical examination disclosed the attachment of tongue to the floor of the buccal cavity throughout its length (Lack of frenulum), disabling the calf to move its tongue and swallow. The findings of physical examination confirmed the condition as ankyloglossia which is a congenital anomaly. All the physiological, hematological and serum biochemical parameters showed no deviation from their standard values. Except for this congenital anomaly, the calf was otherwise normal. The condition was managed by partial frenulectomy on the same day of its presentation.

Treatment and Discussion

The calf was prepared for aseptic surgery after administration of Dextrose normal saline and Ringer's lactate each at the dose rate of 10 ml per kg body weight. The membranous attachment of cranial third of the tongue with floor of buccal cavity was resected in the shape of 'V' under local infiltration analgesia with 0.5% Lignocaine hydrochloride. The bleeding points were cauterized using electro-cautery.

Movement of the tongue was noticed immediately after surgery. Topically, Gentian violet 1 percent solution was smeared over the cut surface in order to control infection once daily for five days. Postoperatively, calf was given intramuscular injections of Streptopenicillin (Bisterpen -V, Alembic Pharmaceuticals limited, India) at the dose rate of 10mg/Kg body weight once daily for 3 days and Meloxicam (Melonex, Intas Pharmaceuticals Limited, India) at the dose rate of 0.2 mg/Kg body weight subcutaneously once daily for 3 days were given.

The calf able to move its tongue in all the directions by third Postoperative day by which time deglutination reflex was found to be normal. Animal was allowed to suckle milk from its dam from third postoperative day and no signs of regurgitation were observed. No postoperative complications were recorded during an observation period of six months.

The present condition was observed in a two day old Ongole calf, which has been considered as a rare finding in calves by Kilic, (2011). Where is in humans this condition is a common finding in infants (Heller *et al.*, 2005). Similar type of condition was also reported by Ramadan (1994) in a camel as "curling of tongue" which was said to be due to shortening of frenum linguae. Mutations in the Tbox genes might be responsible for the development of this congenital condition (Karahana and Kul, 2009), however research is needed to know the association of this condition with mutation of genes.

Ankyloglossia notice in the present case is inferior type as the tongue tip was attached to the floor of oral cavity. Wright (1995) classified ankyloglossia as superior and inferior types basing on the attachment of tongue tip to hard palate or floor of oral cavity. The tongue was attached to the floor of oral cavity throughout its length in the present case. This kind of complete ankyloglossia was reported as an uncommon finding in humans by Kilic 2011 and in animals by Kiliç and Sarierler, (2004).

Regurgitation of milk and drooling of saliva noticed in the present case was thought to be due to functional limitation of the tongue. Similar assumption was also made by Kiliç and Sarierler, (2004) in a German shepherd dog affected with this condition. This disorder needs to be differentiated from lactose intolerance and failure of closure of reticular groove in

calves, which are also characterized by regurgitation of suckled milk. Scrupulous clinical examination can reveal the persistent ventral frenulum of the tongue.

Surgery was performed under local infiltration analgesia in the present case, as the calf was two days old and the procedure was of shorter duration. Contrary to this, similar condition was treated under general anesthesia by Kilc (2011) in a calf and Anwar and Purohit (2012) in a camel calf. The condition was repaired by 'V' shaped Frenuloplasty in the present case which was stated as a suitable technique to treat ankyloglossia in veterinary patients by Kiliç and Sarierler (2004) where as horizontal to vertical frenuloplasty and 'Z' shape Frenuloplasty were preferred in human patients (Lalakea and Messner, 2002). However by performing frenulotomy the conditions like partial ankyloglossia can be treated. Appropriate surgical technique and proper postoperative care rendered an uneventful recovery without any postoperative complications in the present case.

Conclusion

Ankyloglossia is a congenital condition which can be easily diagnosed by observing the clinical signs like regurgitation, difficulty in deglutition and absence of movements of tongue immediately after birth. It can be better treated by Frenuloplasty as performed in the present case.

References

- [1] Anwar S and Purohit GN (2012) Ankyloglossia and its surgical correction by frenuloplasty in a she-camel calf (*Camelus dromedarius*). *Open Vety. Jou.* (2012), Vol. 2: 23-25
- [2] Heller J, Gabbay J, O'Hara C, Heller M and Bradley JP (2005). Improved ankyloglossia correction with four-flap Z-frenuloplasty. *Ann. Plast. Surg.* 54, 623-628.
- [3] Hernandez, SZ and Negro, VB (1999). Surgery of the tongue in the dog. *Diseases and surgical techniques. Canine Pract.*, 24: 11-12.
- [4] Kiliç N and Sarierler M (2004). Surgical correction of a congenital ankyloglossia in an Anatolian shepherd dog. *Ind. Vet. J.*, 81:1271-1272.
- [5] Kilic N (2011). Surgical correction of a congenital partial ankyloglossia in a calf. *Iranian J. Vet. Res.* 12, 357-359.
- [6] Lalakea ML and Messner H (2002). Frenotomy and frenuloplasty: If, when, and how. *Otolaryngol. Head Neck Surg.*, 13: 93-97.
- [7] Nair NR and Bandopadyay AC (1994) Thyroglossal cyst below the base of the tongue with ankyloglossia in a kid. *Ind. Vet. J.* 71, 279-280.

[8] Ramadan RO (1994) Surgery and Radiology of the Dromedary Camel. Ed. R.O. Ramadan King Faisal University, Box 1757, Saudi Arabia. Pp 269.

[9] Rajesh K, Prasad VD, Suresh K, Bose VSC and Sundar NS (2010) Ankyloglossia in an Ongole calf. Indian Veterinary Journal 87(10):1027.

[10] Wright, JE (1995). Tongue-tie. J. Paediatr. Child Health. 31: 276-278.

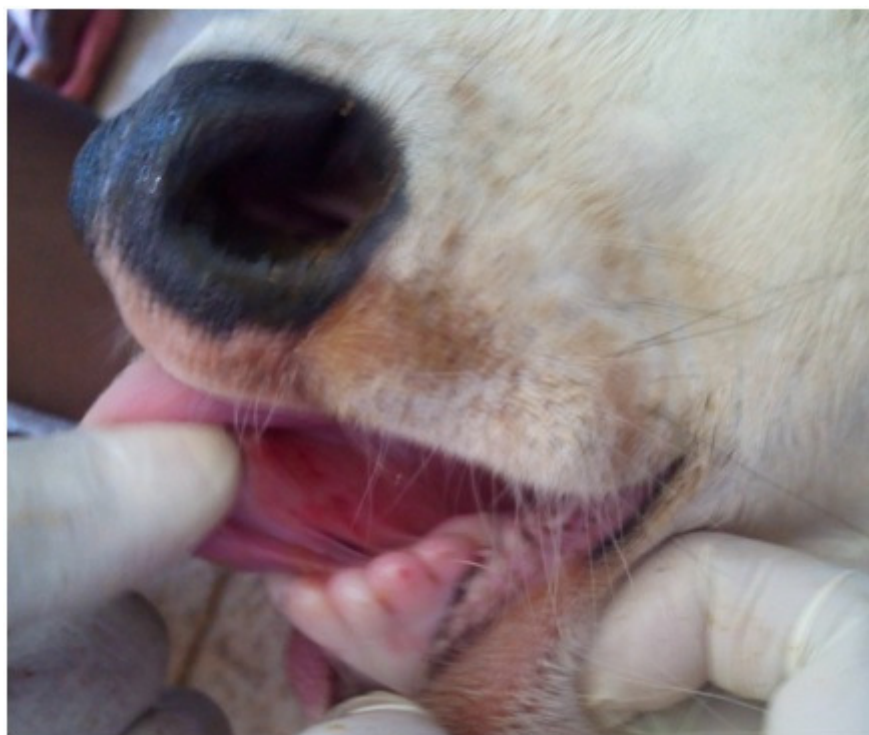


Fig-1: Photograph showing ankyloglossia in a ongole calf