

*Case Report*

**CONGENITAL RECTO-VAGINAL FISTULA WITH ATRESIA ANI IN  
A LAMB: A CASE REPORT**

**V Devi Prasad<sup>1\*</sup>, R Mahesh<sup>2</sup>, G Kamalakar<sup>2</sup> and J Devarathnam<sup>2</sup>**

<sup>1</sup>Associate Professor, <sup>2</sup>Assistant Professor

Department of Veterinary Surgery and Radiology

College of Veterinary Science: Proddatur

Sri Venkateswara Veterinary University, Andhra Pradesh-516 360

E-mail: professorprasad@yahoo.com (\**Corresponding Author*)

**Abstract:** Recto-vaginal fistula and atresia ani in a 3 day old female lamb was diagnosed based on clinical symptoms like passing of dung through the vagina and bulging of the perianal skin at the base of the tail on manual pressing of the abdomen. These congenital defects were corrected surgically under caudal epidural analgesia using 2% Lignocaine hydrochloride. Animal recovered uneventfully without any complications.

**Keywords:** Atresia ani, recto-vaginal fistula, epidural analgesia.

### **Introduction**

Congenital is a descriptive term, denoting a condition existing at birth; hence, congenital deformities are defined as abnormalities present at birth. Congenital defects, abnormalities of structure or function present at birth, may be caused by genetic or environmental factors, or a combination of both: in many cases, the causes are unknown (Shukla et al., 2007). Congenital recto-vaginal fistula is characterized by the connection between the dorsal wall of the vagina and the ventral portion of the rectum, so that the vulva functions as a common opening to urogenital and gastrointestinal tract. Atresia ani is a congenital abnormality characterized by persistence of the anal membrane (Dreyfuss and Tulleners, 1989). This paper communicates surgical management of congenital recto-vaginal fistula with atresia ani in a lamb.

### **Case History and Observations**

A female lamb aged about 3 days was presented to the Department of Veterinary Surgery and Radiology, with a history of absence of anus and passing dung through the vagina (Fig: 1). Upon clinical examination, through vagina a fistulous opening between the rectum and anus was located 1-2 inches cranial to the roof the vaginal wall and floor of the rectal wall (Fig: 2) . Manual pressure on the abdomen resulted in bulging at the base of the

tail and passing of dung through the vagina. Based on history and clinical examination, the condition was diagnosed as recto-vaginal fistula with atresia ani and it was planned to treat the condition surgically.

### **Treatment and Discussion**

After aseptic preparation of the perineal region, caudal epidural analgesia was achieved using 2% Lignocaine hydrochloride. A circular incision was made by joining the ends of the crisscross incision at the base of the tail. Upon blunt dissection, rectal end was approached and mucosa of the rectum was sutured to the perineal skin by simple interrupted sutures at 3, 6, 9 and 12 O' clock positions with braided black silk. To prevent the closure of reconstructed anal opening, barrel a nylon syringe was placed into the rectum and retained in position by interrupted sutures on either side.

A linear incision skin incision of 4-5 cm was made horizontally between the anus and upper vaginal commissure. By blunt dissection of perineal tissues fistulous opening was approached (Fig: 3) and closed the two openings separately by the chromic catgut no 3-0 using simple interrupted sutures. The skin incision was closed in a standard manner. Postoperatively it was administered with Amoxicillin-Cloxacillin 500 mg IM for seven days and meloxicam-1.5 ml SC for three days besides daily dressing of the wound with povidone iodine solution. Animal was administered 3 ml cremaffin<sup>®</sup> BID for five days. Syringe barrel and skin sutures were removed on 5<sup>th</sup> and 10<sup>th</sup> postoperative days respectively. Animal recovered uneventfully without any complications on 10<sup>th</sup> day.

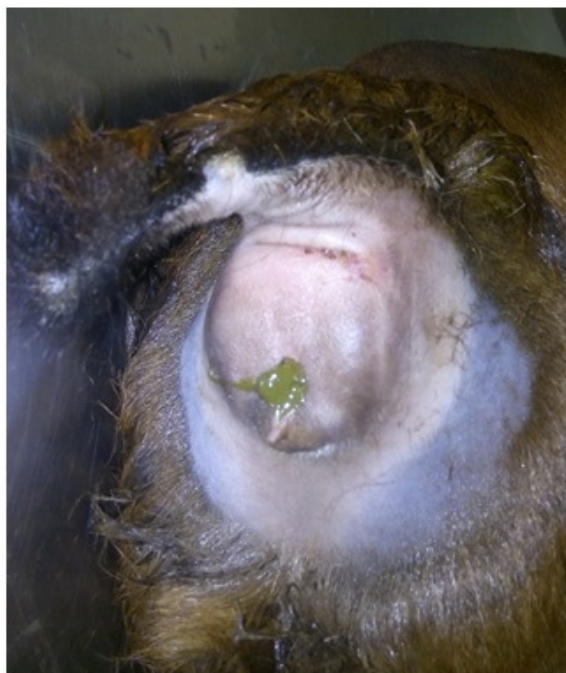Atresia ani is a condition exists on its own or associated with atresia recti, recto-vaginal fistula, rectocystic fistula, vagino-urethral agenesis, taillessness, hypospadias, cleft scrota etc. These congenital malformations have been associated with abnormal chromosomes (Singh et al., 1993). Bademkiran et al., 2009 opined that, any flaws or defects or aberrations in the process of differentiation at the embryological level may lead to congenital defects in the formation of various organs like urethra, vagina and anus etc. In this case, a complex of defects affecting vagina, rectum and anus may be ascribed to the embryological defect in the urogenital folds leading to the malformation. It is concluded that, surgical intervention is the only possible solution to treat such congenital defects in animals to so as to make them survive.

### **Summary**

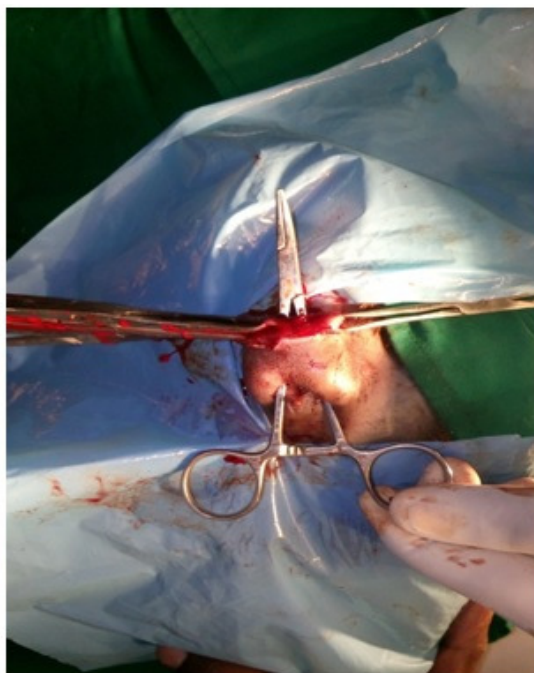Congenital recto-vaginal fistula with atresia ani in a lamb was presented and corrected surgically under caudal epidural analgesia with 2% lignocaine hydrochloride.

## References

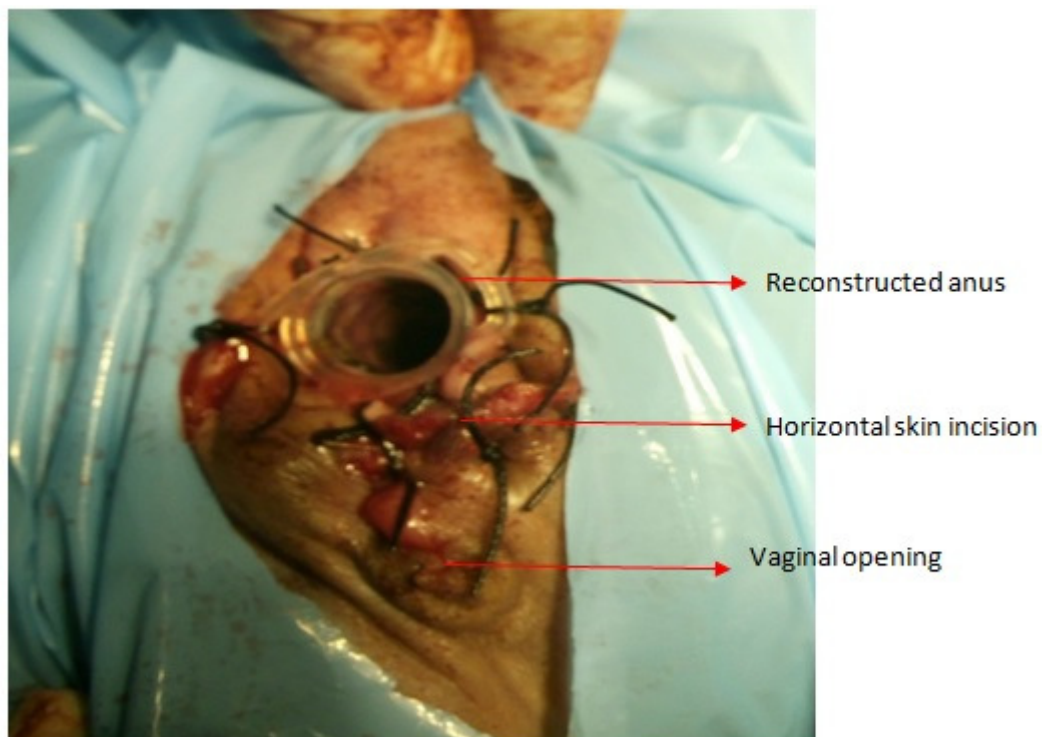
1. Bademkiran S, Icen H and Kurt D (2009). Congenital recto-vaginal fistula with atresia ani in a heifer: a case report. *Y.Y.U.Veteriner Fakultesi Dergisi*: 20(1), 61-64.
2. Dreyfuss DJ and Tulleners EP (1989). Intestinal atresia in calves: 22 cases (1978-1988). *Journal of American Veterinary Medical Association*: 4, 508-513.
3. Shukla SP, Nema SP, Pandey AK and Garg UK (2007). Dystocia due to a bull dog calf in a she buffalo, *Buffalo Bulletin*: 26(3), 104-105.
4. Singh J, Singh AP and Patil DB (1993). The digestive system In: *Ruminant surgery: A text book of the surgical diseases of cattle, buffaloes, camels, sheep and goats* ed: Tyagi RPS and Singh J, CBS publishers and distributors, Pp: 222-223.



**Fig: 1.** Photograph showing passage of dung through vagina and bulging at the base of tail due to atresia ani.



**Fig: 2.** Photograph showing passage of artery forceps through recto-vaginal fistula



**Fig:3.** Photograph showing postoperative appearance of reconstructed anal orifice.