

## **FREE-FORM EXTERNAL SKELETAL FIXATION USING ACRYLIC CONNECTING BARS FOR TREATMENT OF LONG BONE FRACTURES IN SHEEP AND GOAT**

**Mohd Abdul Basith<sup>1</sup>, Makkena Sreenu<sup>2</sup>, EL Chandra Sekhar<sup>3</sup> and N Rajendranath<sup>4</sup>**

<sup>1</sup>Veterinary Assistant Surgeon Veterinary Dispensory, Sangareddy, Telanagana

<sup>2</sup>Professor & Head, Veterinary Surgery & Radiology, NTR College of Veterinary Science,  
Gannavaram, Krishna (dt), Andhra Pradesh

<sup>3</sup>Professor & Head Department of Veterinary Surgery and Radiology,  
College of Veterinary Science, Korutla, Karim Nagr (Dt) Telanagana

<sup>4</sup>Professor, Department of Veterinary Anatomy & Histology  
College of Veterinary Science, Rajendranagar, Hyderabad, 500030

E-mail: drmakkena@yahoo.co.in (<sup>2</sup>Corresponding Author)

**Abstract:** Seven small ruminants presented to Campus Veterinary Hospital, College of Veterinary Science, Rajendranagar were diagnosed to have long bone fractures. Physical examination and Radiography aided in diagnosis. In all the cases, the fracture was stabilized by application of free-form external skeletal fixation using Acrylic connecting bars under sedation with Xylazine Hydrochloride and Intravenous regional anesthesia with 2% Lignocaine Hydrochloride. Fracture healing was assessed periodically by taking plain radiographs. Swelling and discharges from the tracts were recorded during the first three postoperative days in all the treated cases. Complete weight bearing was observed by 36±11.35 days.

**Keywords:** External skeletal fixation, long bone fractures, sheep goat

### **Introduction**

Fracture of long bones are common in small ruminants resulted most of the times by trauma. It requires either conservative management or surgical intervention. The main draw back in surgical intervention is the higher cost of implants required and the expenditure during the postoperative care. As the external skeletal fixation (ESF) is less invasive and requires minimal equipment its use in veterinary practice had increased (Harari *et al.*, 1998). Though the linear ESF serves good for many long bone fractures it has some limitations like no potential for using smaller or larger pins as the transfixation pins size depends on the size of clamps used.

Consequent upon the above mentioned facts, the Free-form ESF has been developed (Martinez *et al.*, 1997) and is gaining acceptance among practicing veterinarians. Free-form ESF allows the transfixation pins placed in the fracture fragments to be connected with

Acrylic material rather than clamps and metallic connecting rods. In the present study management of long bone fractures in sheep and goat by free-form external skeletal fixation using acrylic connecting bars was discussed.

### Material and Methods

The present study was carried out in seven small ruminants with long bone fractures out of which two are sheep (n=2) and five are goat (n=5). The type of fracture and its severity was assessed by physical examination of the animal and radiography of the affected limb. The anamnesis of the animals under the study are as follows.

Case No.	Species	Sex	Age	Breed	Bone involved	Type of fracture	Etiology
1	Goat	F	3months	Jamunapari	Tibia	Oblique	Physical Trauma
2	Goat	F	4 months	Jamunapari	Tibia	comminuted	Automobile Accident
3	Goat	M	2.5 years	N.D	Metatarsal	Oblique	Physical Trauma
4	Goat	F	2 months	Jamunapari	Tibia	Transverse	Fall from Height
5	Sheep	F	4 months	Deccani	Metacarpal	Transverse	Fall from Height
6	Goat	F	2 years	Jamunapari	Metatarsal	Transverse	Physical Trauma
7	Sheep	M	2.5 years	Nellore	Metacarpal	Oblique	Automobile Accident

All the animals were given a first aid for the fracture on the day of their presentation and advised 12 hours fasting prior to surgery. Temporary stabilization of the fracture site was done by application of Robert jones and reinforced Robert jones bandage, till the date of surgery. All the animals were prepared for aseptic surgery and were sedated with intramuscular injections of Xylazine hydrochloride @ 0.05 mg/Kg body weight. Regional anesthesia was achieved by injection of 2% Lignocaine hydrochloride at the dose rate of 2.5mg/Kg body weight into cephalic and saphenous veins depending on the limb affected with a preplaced tourniquet proximal to the area of administration.

All the animals were kept in lateral recumbancy with affected limb touching the table. After reduction of the fracture fragments to their normal anatomical position transfixation pins were drilled (Fig-1) and connected to a 20 mm diameter corrugated plastic tube longitudinally, parallel to the long axis of the bone instead of connecting rods. This was

accomplished by piercing the tube along its width through the free ends of the transfixation pins. The proximal opening of the tube was temporarily closed with micropore tape (Fig-2).

Acrylic (Fig-3) remains in a semi-solid and pourable consistency for a maximum time of about 30-45 seconds from the time of its mixing. After this time it gets solidified progressively. The corrugated tube connected to transfixation pins is filled with acrylic which is in semisolid consistency (Fig-4). A setting time of 11 to 18 min was allowed. The time taken (in minutes) for hardening of the acrylic connecting bar was recorded. Complete hardening occurred in about 11 to 18 minutes with a mean of  $13.85 \pm 1.05$  minutes. The acrylic connecting bars were positioned 10mm away from the skin to reduce the working length of transfixation pins. The exothermic reaction lasted for about 5 to 6 minutes of mixing due to polymerization and was neutralized by pouring refrigerated sterile normal saline over the exposed portions of the transfixation pins. The surgical site was covered with sterile mops during this process. When the hardening of the acrylic was complete, the excess parts of the transfixation pins were cut close to the acrylic bar (Fig-5).

Postoperatively, the pin-skin interface was cleaned with 5% povidone iodine solution and covered with povidone iodine soaked sterile gauze pads. The implant was covered with cotton pad on medial aspect and applied a padded bandage to avoid injury to contra lateral limb. Ampicillin-Cloxacillin (AC-VET® FORTE) was administered parentally at the dose rate of 10 mg / kg weight for five days. Meloxicam at the dose rate of 0.25 mg/kg body weight was administered parentally for three days. The pin tracts were dressed with povidone iodine on alternative days for the first ten days. The owners were advised to restrict the activity of the animal until clinical union was observed. Plain Antero-Posterior radiographs of the operated bones were obtained immediately after surgery and on the 15th, 30th, 45th days, and whenever needed on later dates to access the progress of bone healing.

Following clinical and radiographic union of the fractured bone the External Skeletal Fixators were removed by cutting the pins close to the Acrylic column (Fig-6) and pulling the transfixation pins with a needle holder. All the transfixation pins in animals were removed at once without any staged disassembly. The pin tract sites were cleaned with 5% povidone iodine solution and a sterile dressing pad was applied with a protective bandage for one week.

### **Results and Discussion**

The flexible corrugated plastic pipe of 20mm diameter anchored to the transfixation pins served as a good scaffold for pouring the semi-solid acrylic material. The acrylic material was used in the present study by mixing the powder and liquid components in the ratio of 2:1.

The results showed that the time taken for hardening of the acrylic connecting bar in the ranged from 11 minutes to 18 minutes, with a mean hardening time of  $13.85 \pm 1.05$  minutes.

Immediate post-operative radiographic evaluation revealed proper placement of the fixator, apposition and alignment of the fracture fragments. One of the animals with tibial fracture had disturbed alignment on 2nd day after surgery. This fracture was found to have taken longer time of 64 days for healing. Radiographic examination revealed the acrylic connecting bar to be radiolucent and therefore did not interfere with visualization of the fracture site (Fig-6). Small air bubbles in the acrylic connecting bar were discernible on radiographs as radiolucent areas, but they did not compromise the stability of the ESF assembly.

All the animals in the present study tolerated the external skeletal fixator assembly well except one animal with metacarpal fracture. The fixators were observed to be firm in place in all the remaining six animals (Fig-8). The swelling and discharge from the pin insertion site observed during the first three postoperative days and resolved by the end of the first post-operative week. The surgical incision (limited open approach) and the pin tracts were found dry and healthy during the entire post-operative observation period in all the animals. The ESF were removed from the animals between 48<sup>th</sup> and 57<sup>th</sup> postoperative days with mean time of  $53.33 \pm 1.86$  days. Following cutting of the transfixation pins during removal of the external skeletal fixators, all the proximal pins were found to be loose in all the animals. Following disassembly of the fixators, slight bleeding and discharges were noticed for three days. This discharge, however, resolved by the end of three days due to routine dressing of these wounds.

In the present study, two animals with closed tibial and metatarsal fractures showed partial weight bearing from 1st and 3rd post-operative day and achieved complete weight bearing by the 5th and 13th day respectively. These animals showed slight limping after the second week but resumed complete weight bearing after the fixator was removed on 57th and 62nd day respectively. Full weight bearing was observed in the other animals between 5th to 64th days with a mean of  $36 \pm 11.35$  days. The mean lameness scores in the animals were recorded as  $1.33 \pm 0.21$ ,  $1.33 \pm 0.21$ ,  $1.33 \pm 0.21$  and  $2.33 \pm 0.5$  at the end of 1st, 2nd, 4th and 6th week of observation respectively.

Based on the observations of the present study it was revealed that the fractures were more commonly seen in female goats when compared to their male counterparts. Singh et al. (1983), Arora (1996) and Dandekar (2007) also made similar observations. This is in variance with the observations of Philip et al. (1998) and Kushwaha et al. (2011) who found

fractures more commonly in male sheep and goats. It was observed from the results of the present clinical study that automobile accidents were the most common cause of fractures in small ruminants followed by physical trauma and fall from a height. Physical trauma, in this context, referred to violence, i.e. the sheep and goats being beaten either by the owners or strangers. Aithal et al. (1998) and Dandekar (2007) also made similar observations. However, Kushwaha et al. (2011) stated that fall from a height or jumping was the most commonly found exciting cause of fractures in sheep and goats.

The patient preparation and anaesthetic protocol followed for the surgery was found satisfactory in all the animals for management of fracture in the present study. Hall et al. (2001), Ramanathan et al. (2006) and Kumar et al. (2008) also recommended similar patient preparation and anaesthetic protocols for fracture management in sheep and goats.

Fixing the corrugated tube to the free ends of transfixation pins was done by applying slight pressure. Acrylic was prepared by mixing powder and liquid at the ratio of 2:1 and the prepared semi-solid mixture was poured in to the attached corrugated tube within 30-45 seconds so as to complete the procedure before solidification of acrylic. Piermattei et al., (2006) also made similar recommendations. The results indicated that it required about 11 to 18 minutes for hardening of the acrylic material. To counteract the ill effects of heat generated, about 4 to 6 minutes after mixing of acrylic, refrigerated normal saline was poured over the transfixation pins and pin-skin interface for about 5 to 6 minutes, the time interval during which the exothermic reaction occurred.

Cleaning the transfixation pin-skin interface with normal saline and dressing with 5% povidone-iodine pads resulted in clean and dry pin-skin interface. Harari et al. (1998) suggested daily cleaning with dilute antiseptic solutions like chlorhexidine and povidone-iodine post-operatively to treat pin tract drainage. Ozak et al. (2009) also suggested the use of antibiotic spray for possible pin tract infections during convalescence period. Post-operative swelling of the affected limb observed for first 3 to 5 days in all the animals was considered a normal consequence of the surgical procedure. It also suggested that this swelling should be considered clinically inconsequential if it is not accompanied by discharge of pus or foul smelling discharges.

In all the animals of the two groups, loosening of the proximal most pin accompanied by healthy discharge at the time of ESF disassembly was evident due to excessive local stress on the upper most transfixation pin leading to bone resorption. Kraus (2003), Beck and Peard (2003), Gemmill et al. (2004) and Corr (2005) also made similar observations.

Despite the presence of small air bubbles in the acrylic connecting bar, the results indicated that this did not interfere with the stability of the construct. During the routine post-operative assessment when the animals were made to walk during the subsequent visits, it was observed that the ESF constructs were stable and did not appear to be causing any difficulty to the patient while at rest or in motion. Loosening of the proximal most pin was found in all the animals with less effect on the stability of ESF construct. Kraus et al. (2003) recognized that a good clinical result can sometimes be achieved in spite of a rapidly loosening and failing fixator. Johnson et al. (1989), Lewis et al. (2001) and Fox (2008) also opined that pin loosening was normal progression with external skeletal fixation. Kraus et al. (2003) managed similar complications by placing additional pins and connecting bars to enhance the strength and rigidity of the construct. Finally, it was concluded that acrylic connecting bar is suitable for free-form external skeletal fixation for management of long bone fractures in sheep and goats.

#### **Acknowledgements**

The authors are thankful to the authorities of Sri Venkateswara Veterinary University for the facilities and to Dr KBP Raghavendar, Professor & Head, Department of Veterinary Surgery & Radiology, College of Veterinary Science, Rajendra Nagar, Hyderabad for timely help in conduct of research.

#### **References**

- [1] Aithal H P, Singh G R and Bist G S 1998. Incidence of fractures in different domestic animals-A twenty year survey analysis. Paper presented in XXII Annual congress of Indian Society for Veterinary Surgery, convention, Bhubaneswar, Nov. 5-7.
- [2] Arora 1996. Clinical and radiological evaluation of fractures in goats. M.V.Sc. Thesis submitted to Rajasthan Agricultural University, Bikaner.
- [3] Beck A L and Peard M J 2003. The Use of Ellis pins (negative profile tip-threaded pins) External Skeletal Fixation in Dogs and Cats. *Veterinary Comparative Orthopaedics and Traumatology*. 16: 223-31.
- [4] Corr S 2005. Practical Guide to Linear External Skeletal Fixation in Small Animals. In *Practice*. 27: 76-85.
- [5] Dandekar S V 2007. Study on the efficacy of external fixation technique to repair lower limb fractures in goat M.V.Sc. Thesis submitted to department of surgery and radiology, College of Veterinary and Animal Sciences, Parbhani. Maharashtra Animal and Fishery Sciences University, Nagpur.

- [6] Fox D B 2008. Principles of External Fixation for Fracture Repair. Proceedings of the International SCIVAC Congress.184-185.
- [7] Gemmill TJ, Cave TA, Clements DN, Clarke SP, Bennett D and Carmichael S 2004. Treatment of Canine and Feline Diaphyseal Radial and Tibial Fractures with Low-stiffness External Skeletal Fixation. *Journal of Small Animal Practice*. 45:85-91.
- [8] Hall LW, Clark KW and Trim CM 2001. *Veterinary Anaesthesia* 10th edition, W.B. Saunders Company. Philadelphia. 331.
- [9] Harari J, Seguin B and Padgett S L 1998. Principles of External Skeletal Fixation in Small Animal Surgery. *Veterinary Medicine*. 93: 445-453.
- [10] Johnson AL, Kneller SK and Weigel R M 1989. Radial and Tibial Fracture Repair with External Skeletal Fixation: Effects of Fracture Type Reduction and Complications on Healing. *Veterinary Surgery*. 18: 367-372.
- [11] Kraus KH, Toombs J P and Ness M G 2003. *External Fixation in Small Animal Practice*. I ed. Blackwell Science Ltd Oxford UK.5-98.
- [12] Kumar R, S K, Guha, Kumar D, Singh M K, Imran Ali 2008. Studies of acrylic external skeletal fixation technique to repair tibial fracture in goats. *Journal of Interacademia* 12(1): 91-94.
- [3] Kushwaha R B, Gupta A K, Bhadwa M S, Sharadkumar L and Tripathi A K 2011. Incidence of fractures and their management in animals: a clinical study of 77 cases. *Indian Journal of Veterinary Surgery* 32(1): 54-56.
- [14] Lewis D D, Cross A R, Carmichael S and Anderson M A 2001. Recent Advances in External Skeletal Fixation. *Journal of Small Animal Practice*. 42: 103-112.
- [15] Martinez S A, Arnoczky S P, Flo G L and Brinker W O 1997. Dissipation of Heat During Polymerization of Acrylics used for External Skeletal Fixator Connecting Bars. *Veterinary Surgery*. 26: 290-294.
- [16] Ozak A, Yardimci C, Nisbet H O and Sirin Y S 2009. Treatment of Long Bone Fractures with Acrylic External Fixation in Dogs and Cats: Retrospective Study in 30 Cases (2006-2008). *Journal of the Faculty of Veterinary Medicine*. Kafkas University 15(4): 615-622.
- [17] Piermattei D, Flo G and DeCamp C 2006. *Handbook of Small Animal Orthopedics and Fracture Repair*. Elsevier Inc Missouri USA.
- [18] Philip D, Ameerjan K, Thilagar S and Archibald W P 1998. A retrospective study of bone and joint disorders in farm and pet animals. Paper presented in XXII Indian Society for Veterinary Surgery, Symposium, Bhubneshwar in November, 5-7.

[19] Ramanathan A, Ganesh TN, Murali Manohar B and Haider S 2006. External skeletal fixation of metacarpal fracture in calves: A Clinical Evaluation. Journal of Research, SKUAST- J, 5(2):135-138

[20] Roe SC and Keo T 1997. Epoxy Putty for Free-Form External Skeletal Fixators. Veterinary Surgery 26:472-477.

[21] Singh AP, Mirakhur KK and Nigam JM 1983. A study on the incidence and anatomical locations of fractures in canines, caprine, bovine, equine and camel. Indian Journal of Veterinary Surgery 4(1): 61-66.

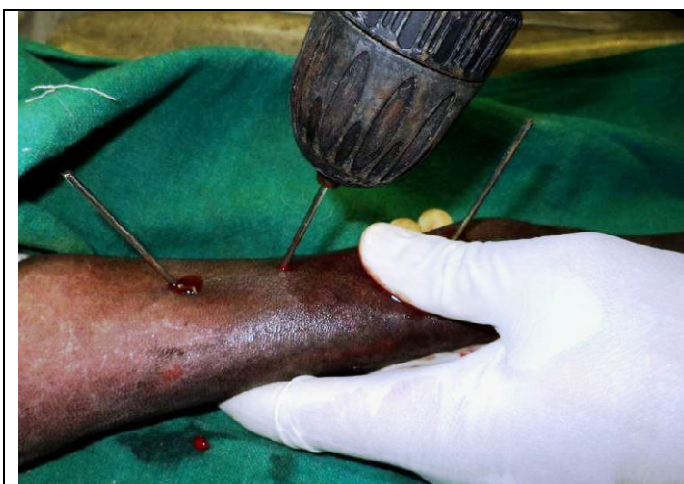

Fig.-1: Photograph showing placement of transfixation pins

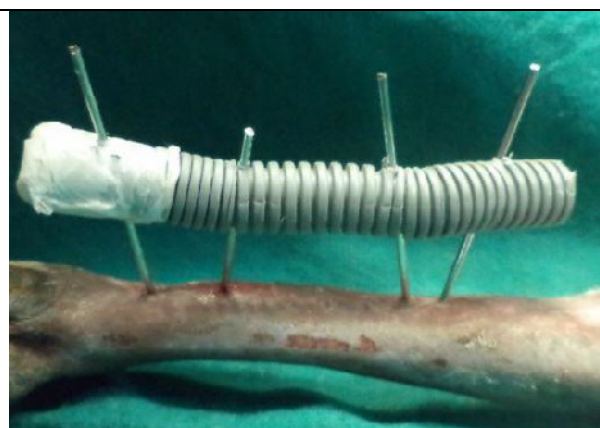


Fig-2: Distal opening of the tube temporarily closed with micropore tape

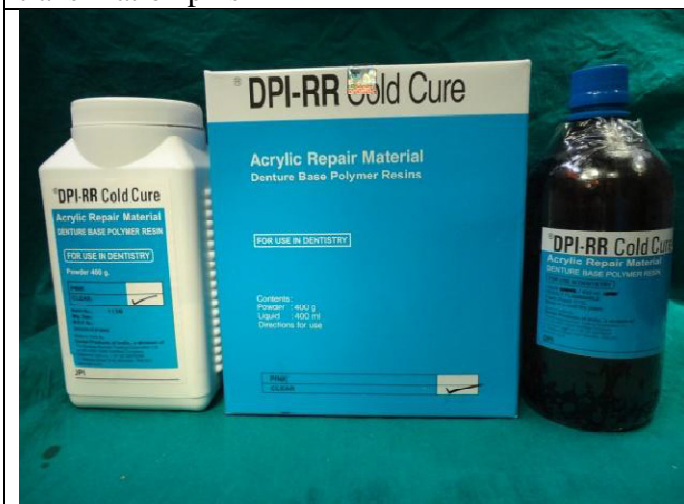

Fig -3: Photograph showing commercially available Acrylic Repair Material(DPI-RR Cold Cure)

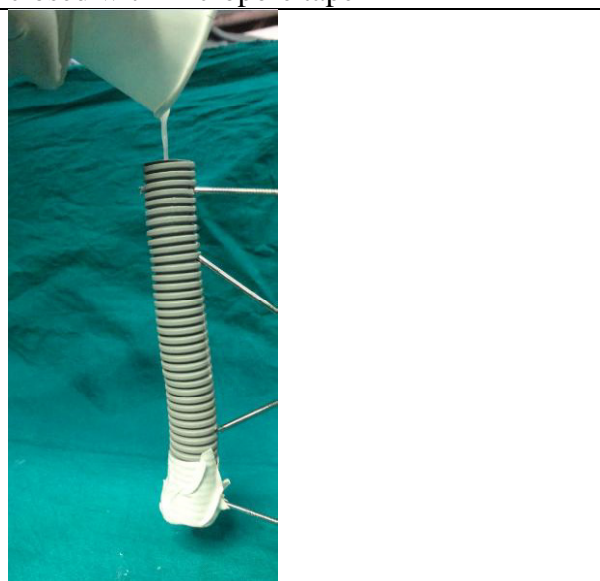

Fig-4: Photograph showing pouring of semisolid acrylic material into corrugated tube



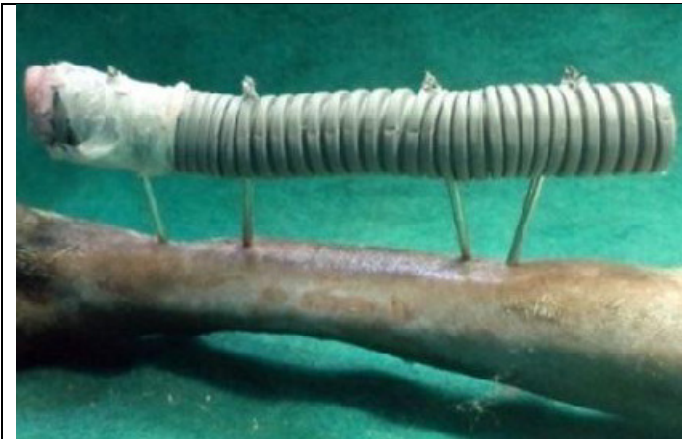

Fig-5: Excess parts of the transfixation pins cut close to the acrylic bar



Fig-6: Cutting the pins close to the acrylic column

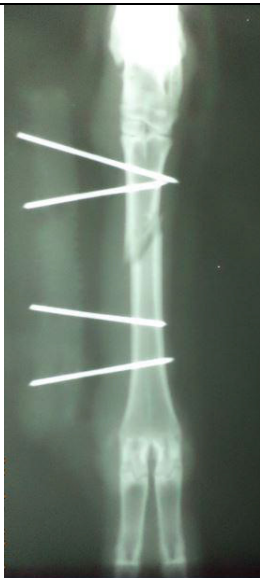

Fig-7: Radiograph showing fracture healing of metacarpal treated with free form ESFusing acrylic material on 1st, post-operative day

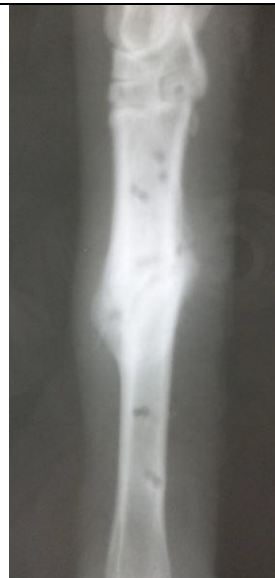

Fig-8: Radiograph showing fracture healing of metacarpal treated with free form ESFusing acrylic material on 48th post-operative day.