

RADIOGRAPHIC EVALUATION OF POLY METHYL METHACRYLATE AND HYDROXY APATITE IMPLANTS FOR FRACTURE HEALING IN RABBITS

K. Harsha Vardhan, V. Devi Prasad*, Makkena Sreenu and N. Syaama Sundar

Department of Veterinary Surgery and Radiology
NTR College of Veterinary Science, Gannavaram – 521101 (Andhra Pradesh)

Abstract: Polymethyl methacrylate (PMMA) implants and Hydroxy apatite paste (HA) were employed to treat the experimentally created mid diaphyseary fractures in rabbits (n=24). PMMA implants were designed that resemble K-wires. K-wires of 1.0 to 2 mm diameter were employed to immobilize the fracture fragments in one group (Control; n=8). In the second group, PMMA implants were employed for the same purpose (Group II); while in the third group (n=8), the HA paste was stuffed in to the medullary cavity of the fracture fragments, before passage of K-wires. A series of radiographs were obtained at the end of 30, 45 and 60 days in all the rabbits and the pattern of bone healing was assessed. It was concluded that, animals of PMMA group showed early callus formation when compared to the other two groups.

Keywords: Poly methyl methacrylate, Hydroxy apatite, K-wires, radiological union, callus formation.

Introduction

Veterinary orthopedic surgeons have been trying to find out some of the internal skeletal fixation methods and devices to treat complicated and overriding fractures in animals. Both in human beings and animals, the removal of the implants is required after the clinical and radiological union is accomplished and the function of the limb is restored. In the recent past, the interest has been shifted to find out the some of the degradable and absorbable implants which aid in reduction and get degraded or absorbed after some time. Bioceramics (hydroxyapatite, tricalcium phosphate, dicalcium phosphate, bioactive glass, calcium sulphate), polymers (Polylactic acid, polyglycolic acid and polymethylmethacrylate), metals (stainless steel, titanium and titanium alloys, cobalt-chromium) and composites (ceramic-metal, ceramic-polymer, ceramic-ceramic) have been tried by several researchers. In the present study, an attempt was made to use and compare PMMA and HA to immobilize the overriding mid diaphyseary fracture in rabbits.

Materials and Methods

The present study was carried out to explore the usefulness of PMMA and HA implants in the internal fixation of long bone fractures in rabbits. This experiment was conducted in 24 rabbits with the prior approval of Institutional Animal Ethics Committee (IAEC). Twenty-four rabbits were randomly divided into three groups of eight each. In group I, the fracture fragments were immobilized using simple K-wires and were kept as control. In group II (n=8), PMMA implants were prepared by placing the paste of PMMA powder by adding to a liquid monomer in a stain less steel mold. After completion of setting, the edges of the implant were trimmed off and the resultant implant (Fig 1,2 and 4) was used as a K-wire to immobilize the fracture fragments. In group III (n=8), hydroxy apatite (Fig 2) paste was stuffed in to the medullary cavity of both the fracture fragments and routine intramedullary pinning using K-wires was carried out. A standard craniolateral incision over the thigh was placed and routine intramedullary pinning was performed under general anesthesia using xylazine (@ 5 mg/Kg) and Ketamine (@ 35 mg/Kg), in all the groups, Postoperative treatment with broad-spectrum antibiotics and analgesics was carried out. A series of radiographs were obtained after 15, 30, 45 and 60 days intervals to assess the radiographic union of bone healing.

Results and Discussion

On day 15, radiographs were taken in all the groups. In control group, callus formation was seen but one animal developed a secondary chip fracture (Fig 5). In one animal, there were osteolytic changes, indicated by radiolucent area near the fracture site (Fig 6). In PMMA group, the callus formation was evident and was superior to that of control group. In HA group, excessive callus was noticed at the fracture site. The complication of pin migration in control group can be attributed to K wire which has a smooth surface and lacks the capability to neutralize the rotational force. The excessive callus formation in hydroxyapatite group might be due to the osteoinductive property of HA. At 30 days in control group, one animal showed malunion and the other animal developed a secondary fracture. In PMMA group, unorganized hard callus was seen around the fracture line with the fracture fragments in proper alignment (Fig 7). In hydroxyapatite group, reasonable radiological union of fracture fragments could be noticed but with a line of radiolucency. Malunion observed in this group was thought to be due to osteomyelitis. However, in PMMA group, progressive and satisfactory bone healing was observed without any complications of osteomyelitis. Though the healing of the fractured bone was satisfactory in hydroxyapatite group, it was lesser than

the PMMA group, which might be due to increased stress because of the metal implant usage in hydroxyapatite group.

At 60 days in control group, though there was union of the fracture fragments it was not without side effects. In PMMA group, healing was complete with total resorption of exuberant callus (Fig 8). In HA group, general radio-opacity of the bone increased along with good fracture union. Superior healing in PMMA group was due to the rotational stability of the PMMA implant which is lacking in K wire. The designed PMMA implant was an exact fit to the medullary cavity of femur because of which it was capable of neutralizing rotational forces better than K wire. In HA group, increased bone density (Fig 9) can be attributed to the osteoinductive property of HA and by the end of sixty days, complete radiographic union was evident (Fig 10). These results are in accordance with those of Miranda *et. al.* (2005), Ciani *et. al.* (2006), Adamiak and Rotkiewicz (2010) and Pike *et. al.* (2012). Miranda *et. al.* (2005) used hydroxyapatite and calcium triphosphate implants for repair of experimentally induced fractures of radius in rabbits. At 60 days it was found that there was no evidence of fracture line radiologically. Ciani *et. al.* (2006) observed that, at the end of 60 days, there was complete healing as shown by bone bridge uniting the fracture fragments. Adamiak and Rotkiewicz (2010) from their studies on tibial fractures in sheep reported that there was complete bone union radiologically in between days 52 and 68 after surgery. Pike *et. al.* (2012) from their experiments with PMMA cement found that, there was good union after 8 weeks in 6 out of 13 dogs treated. PMMA was found to be more suitable in the treatment of femoral diaphyseal fractures due to its rigidity on solidification, complete filling of the bone marrow which offer stability by avoiding rotational forces, perfect union of the fracture site and no need of implant removal following surgery. The PMMA can be designed as per required the size and shape Though, HA showed better healing than control group, it has disadvantages like pin migration, excess cicatrization and its difficulty to be molded in to the desired shape and size although it showed better osteoinductive property. Hence the PMMA implant can be a better choice to treat fractures for quick healing and an alternative for routine intramedullary pins.

Summary

Better radiographic union of experimentally created femoral diaphyseary fractures was seen in rabbits treated with PMMA implants followed by Hydroxy apatite group, when compared to the simple intramedullary pinning carried out with K-wires.

Acknowledgements

The authors thank the authorities of Department of Biotechnology, New Delhi for providing financial support for carrying out this research project.

Literature Cited

- [1] Adamiak Z and Rotkiewicz T 2010 A histological evaluation of bone calluses in the treatment of tibia fractures in sheep with the use of a semi-circular fixator. *Veterinarni Medicina*, 55(11): 547-550.
- [2] Ciani R B, Rahal S C, Volpi R S, Taga R, Farmer J M, Cestari T M and Mamprim M J 2006 Mixture of Bone morphogenic Protein, Hydroxyapatite , Inorganic bone and collagen interposed by pericardium membrane in the filling of segmental bone defects in rabbits. *Brazilian Archive of Veterinary Medicine and animal Science*. 58(1)
- [3] Miranda E S, Cardoso F T S, Filho J F M, Márcio D, Barreto A R, Teixeira R M M, Wanderley A L and Fenandes K E 2005 Organic and inorganic bone graft use in rabbits radius surgical fractures repair: an experimental and comparative study. [Acta Ortopédica Brasileira](#) 13(5):245-248.
- [4] Pike F S, Kumar M S A and Boudrieau R J 2012 Reduction and fixation of cranial cervical fracture/ luxations using screws and polymethylmethacrylate (PMMA) cement: a distraction technique applied to the base of the skull in thirteen dogs. *Veterinary Surgery* 41:235–247.

Photographs:



Fig 1. PMMA Powder



Fig 2. Hydroxy apatite granules



Fig 3: Mold used to prepare the PMMA implant




Fig 4. The central image corresponds to the PMMA implant to be trimmed off at the edges.

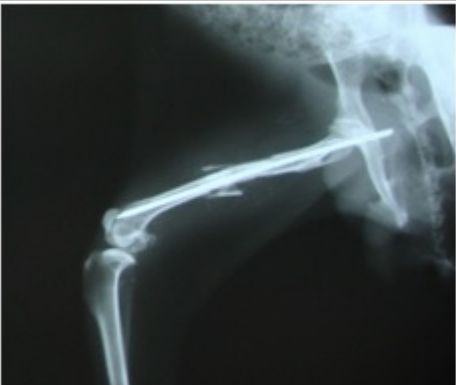

Fig 5. Note Secondary fracture with pin migration in control group.

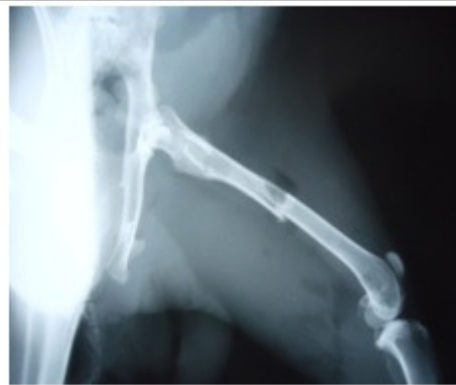

Fig 6. Note mild osteolytic changes in the proximal fragment in group I.

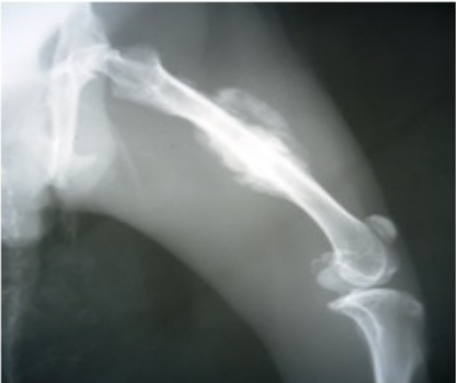

Fig 7. Note hard callus formation bridging of fracture gap in PMMA group by day 30.

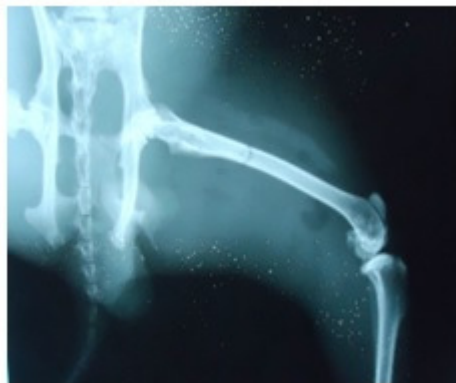

Fig 8. Note near normal bone healing in PMMA group after 60 days.

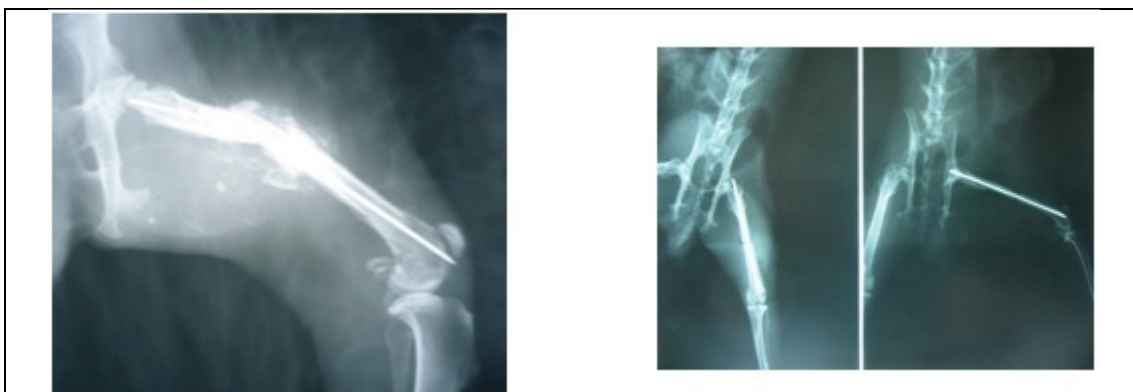

Fig 9. Note exaggerated osteoinductive activity by day 30 (HA)

Fig 10. Note complete bone union in HA group, by day 60.