

RADIOGRAPHIC VIEWS FOR ASSESSMENT OF CHANGES IN CARDIOPULMONARY STRUCTURES IN RELATION TO AGING IN DOGS

Naga Gowthami. G V¹, Makkena Sreenu², Devi Prasad V³ and Venkata Naidu G⁴

¹Contract teaching faculty, ²Professor & Head, ³Professor, ⁴Associate Dean

^{1,2&3}Dept of Veterinary Surgery & Radiology

NTR College of veterinary science Gannavaram – 52 101 (AP)

⁴College of Veterinary Science Garividi, Vizianagaram 535 101 (AP)

Abstract: Difference in various radiographic views for thoracic radiography of thorax like right lateral view (RLV), Left lateral view (LLV), ventrodorsal (VD) and dorsoventral (DV) was recorded. Choosing the different views to diagnose the various disease conditions of thoracic structures and their merits and demerits are discussed. The radiographic features of heart and pulmonary structures are documented.

Keywords: Radiography, thorax, Cardiopulmonary, Geriatric dogs.

Introduction

Radiographic examination is considered as the first modality, after the clinical examination and most useful non- invasive technique and provide rapid and valuable information in the diagnosis (Rudolf *et al.*, 2008). Geriatric dogs experience many changes in the functions of their body systems than other age groups. As per the standard radiographic procedures orthogonal projections will be attained to read the radiological features in any part of the body (Brinkman *et. al.*, 2006). The purpose of this study is to describe the importance of radiographic views for diagnosis of the cardiac as well as pulmonary as observed commonly in aged dogs and to correlate this appearance with associated morphologic alterations.

Materials and methods

A 500 mA X-ray machine (Seimens) with computed radiography system (Carestream) was utilized to undertake the radiographic study in 153 clinical cases of geriatric dogs. Aged dogs randomly selected with irrespective of sex and breed with age of 7- 14 and above years. The dogs were radiographed in different views Viz. right lateral (RLV), left lateral (LLV), Ventrodorsal (VD) and Dorsoventral (DV) views with required recumbency in a standard position arrangement. A sand bag was placed on either side of thorax or beneath the sternum as per need to make the thoracic spine and sternum parallel to each other and to prevent

*Received Mar 7, 2018 * Published April 2, 2018 * www.ijset.net*

movement. The exposure was given when the dog was in full inspiration phase with the range of 55-65 Kvp, mA-80. The radiographs evaluated for roentgen signs and the results were initially calculated by tally marks and then subjected to fisher test for any significant difference in between the breeds.

Results and Discussion

Radiographic features of the heart and pulmonary structures of the thorax were observed and described. Any Specific pathology noted in various organs of thorax was described in terms of radiological features related to cardio pulmonary organs. Radiographic procedure followed in the present study i.e recording four views for the prospective study yielded in satisfactory data. Kealy and McAlister (2005) opined that for a comprehensive study of thorax two oppositional lateral views and either a dorsoventral or ventrodorsal views are useful and the radiographs should be made during inspiratory phase. Examination of the thorax in a systematic way will provide details of the appearing radiological signs without any missing lesions as reported by Berry (2010). Kealy and McAlister (2005) suggested either an organ approach or area approach for the interpretation of any radiograph as practiced in the present study.

Heart

The Right lateral views of thorax obtained from the geriatric dogs revealed 8.03, 12.5, 16.96, 8.03, 5.35, 4.46 and 15.17 percentage of left atrial, left ventricular, right atrial and right ventricular enlargement, vascular, caudal vena caval changes and pericardial effusions respectively, while the percentages were 5.49, 10.98, 14.28, 13.18, 5.49 and 3.29 and 10.98 on left lateral views. On dorso ventral view of the thorax 13.33, 13.33, 17.77, 33.33, 20.00 and 2.22 percentages of positional shift, left atrial, left ventricular, right atrial and right ventricular enlargement, caudal vena caval changes and pericardial effusion were observed. On ventrodorsal view the positional shifts, left atrial, left ventricular and right atrial enlargement (Fig. 1) were 3.77, 15.09, 7.54 and 20.75 respectively. The details of the cardiac silhouette were observed in all the views followed in the present study. Avner and Kirberger (2005) studied the effect of various thoracic radiographic projections on the appearance of selected thoracic viscera. The DV projection appears to be more reliable for assessing the cardiac silhouette, the descending aorta and the angle of divergence of the principal bronchi. The VD projection should be considered for evaluating the cranial vena cava while, right lateral view be used for assessing the descending aorta and cranial vena cava.

The cardiac enlargements observed in the present study might be due to various cardiovascular diseases which will be quantitatively seen as a cardiomegaly in aged dogs. Loss of cranial waist was the indicative of right ventricular enlargement (Burk and Feeney 2003). This enlargement may either be due to dilation of the ventricular diameter or hypertrophy of ventricular wall. On the other hand, radiographic evidence of loss of both cranial and caudal waists of the cardiac silhouette was indicative of generalized enlargement of the heart wherein several chambers may be enlarged (Bahr 2007). Most of the cardiac silhouette abnormalities were commonly observed in aged dogs. The loss of both cranial and caudal waists was also seen in old ones. These observations may be related to an ongoing cardiovascular changes associated either with diseases or ages reported by Guglielmini (2003)

Thoracic radiographs in provide valuable information relative to cardiac size, gross chamber abnormalities, alteration in the size and appearance of great vessels, distortion of the pulmonary and cardiovascular vessel size, abnormalities of the chest wall, pleural space, and the lung itself particularly the bronchi, interstitial spaces and alveolar tissues as reported by Fox (2007). Vascular pattern include hyper vascularization due to increase in size and number of blood vessels that extends to the lung field (Kealy and McAllister 2000). Dilation of the pulmonary arteries were seen in some dogs. They are either in combination with loss of cranial waist or loss of both cranial and caudal waists.

Various authors diagnosed the cardiac enlargements radio graphically. Kibar and Alkan (2005) evaluated the radio graphical findings of heart diseases in geriatric dogs. Wisner (2009) studied the developmental cardiopulmonary disorders of the dog and suggested a clock-face analogy can be used to evaluate specific cardiac chamber size on dorsoventral and lateral radiographs. Lamb and Boswood (2002) used thoracic radiography routinely to assess cardiac size and shape. Oyama (2011) observed that left-sided heart enlargement manifested as increased vertebral heart size, increased height of the cardiac silhouette/loss of thecaudal cardiac waist on lateral projection, left auricular enlargement at the 2- to 3-o'clock position on the dorsoventral or ventrodorsal projection. Pericardial effusion usually occurs without any underlying cause Gugjoo *etal.*, (2014) while Mellanby *et al.* (2002) identified idiopathic pericardial effusion in dogs. The changes in the caudal vena cava might be due to the surrounding structure pathology. Lehmkuhld *et al.* (1997) evaluated the caudal vena cava size radiographically in dogs. Dilation of the caudal vena cava (CVC) on lateral thoracic radiographs was often interpreted as suggestive of right-sided congestive heart failure. Avner and Kirberger (2005) suggested VD projection evaluating the caudal vena cava.

Pulmonary structures

The thoracic radiographs of the on right lateral views revealed 45.53, 17.86, 25.00, 25.89 and 39.28 percentages of interstitial, vascular, bronchial, alveolar, mixed patterns while the same were 35.16, 10.99, 9.89, 38.46, and 28.57 percentages on left lateral views respectively. The radiological features like bronchial mineralization, peribronchial thickening, cavitory lesions, lobar signs, consolidated lung, pneumothorax, and generalized increased opacity of lungs were 33.93, 35.71, 7.14, 8.03, 33.93, 4.46 and 19.64 percentages on right lateral views and the same were 19.78, 24.18, 3.29, 3.29, 29.67, 5.49 and 13.19 on left lateral views respectively in geriatric dogs. The thoracic radiographs on dorsoventral views obtained from the geriatric dogs revealed 33.33, 6.67, 55.56, 26.66 and 35.56 percentage of interstitial, vascular, bronchial and mixed, patterns whereas the same were 60.38, 16.98, 62.26 and 37.73 on ventrodorsal views respectively. A percentage of 5.66 thoracic radiographs and 6.67 percentage on dorso ventral view revealed alveolar patterns and lobar signs respectively. The radiographs of the right lateral views obtained from the geriatric dogs revealed more percentage of interstitial pattern followed by mixed, alveolar, bronchial and vascular patterns where as the left lateral view depicted more percentage of bronchial followed by interstitial, mixed, vascular and alveolar patterns. The dorso ventral view did not reveal any alveolar patterns but some percentage of bronchial, interstitial, mixed and vascular patterns.

The ventrodorsal radiographs reveal more percentage of bronchial followed by mixed and vascular patterns. The radiological features like bronchial mineralization, peribronchial thickening, cavitory lesions, lobar signs, consolidated lung, pneumothorax, and generalized increased opacity of lungs were varied in percentages among the lateral views while dorsoventral or ventrodorsal views did not reveal any of the these lesions except bronchial mineralization in few radiographs in the lung field, these findings are in accordance with Mantis *et al.*, (2008). On the other hand, alveolar pattern has radiologic characteristics of poorly defined, increased densities with fluffy, indistinct margin that tend to coalesce as reported by Fox(2007). The thorax was a complex anatomical area and thoracic radiographs, particularly pulmonary structures, are some of the most challenging radiographic studies to interpret (Thrall, 2013).

The pulmonary patterns and other radiological features observed were the interstitial, vascular, bronchial, alveolar and mixed patterns in geriatric dogs. The pulmonary patterns present on the lung fields were described and categorized as alveolar, interstitial, bronchial and vascular pattern as reported by Kealy and McAllister (2000). The right lateral views of

thorax in geriatric dogs reveal more percentage of interstitial pattern followed by mixed, alveolar, bronchial and vascular patterns whereas the left lateral view depicted more percentage of bronchial followed by interstitial, mixed, vascular and alveolar patterns. Dorsoventral views did not reveal any alveolar patterns but some percentage of bronchial, interstitial, mixed and vascular patterns (Fig no 2). The ventrodorsal radiographs revealed more percentage of bronchial followed by mixed and vascular patterns. The radiological features like bronchial mineralization, peribronchial thickening, cavitory lesions, lobar signs, consolidated lung, pneumothorax, and generalized increased opacity of lungs were varied in percentages among the lateral views while dorsoventral or ventrodorsal views did not reveal any of these lesions except bronchial mineralization in few radiographs. Interstitial infiltrates are those in which there was infiltration of cells, fluid or fibrous tissue into the lung interstitium, without filling the alveoli (Suter and Lord, 1974). In interstitial disease, however, the lung density is not usually sufficient to obscure the vessels. Bronchial patterns are the normal aging changes especially in chondrodystrophic dogs. The markings are linear (tramlines) and ring-like (doughnuts) and the size and clarity of the marking depends on the pathology. Small, peripheral bronchial markings just make the lungs appear scruffy. The vascular pattern may be less prominent due to border effacement. Bronchiectasis produces wavy or wide tramlines and large doughnuts.

Bronchial Calcification was the common finding in older animals. The bronchi appear as linear calcific opacities traversing the lung fields. Often there are almost parallel calcified linear shadows outlining the bronchus in that area as observed by Kealy and McAlister (2005). The bronchial pattern was characterized by thickening of the bronchial walls which normally are not visible or only faintly visible, until they are seen as thin parallel, sometimes irregular lines, or circles when seen end-on. Bronchitis, calcification and bronchiectasis are causes of this pattern. The bronchi are not usually visible except in old dogs, Air bronchograms were when alveoli are flooded, the normal pulmonary structures were obscured. The air-filled branching bronchi however, become visible as well-defined dark radiolucent structures in contrast to the surrounding radio-opaque lung Suter and Lord (1974). The vascular pattern represents a change in the appearance of blood vessels may be hypervascularization, hypovascularization, vascular dilatation and tortuosity. The vascular pattern is caused by haemodynamic changes which increase or decrease the diameter of the pulmonary arteries and/or veins as recorded by Suter and Lord (1974). An alveolar pattern

results when alveoli been filled with fluid, cellular debris or neoplastic infiltrate or when they collapse and these were ill defined fluffy densities appear as cotton wool.

Aging of the lungs of old dogs characterized radiographically prominent interstitial patterns, pleural thickening, calcification of larynx, trachea and bronchial wall, calcification of costochondral junction, new bone growth on the sternum and spondylosis (Kealy and McAlister 2005). The common pulmonary patterns showed that majority of the pulmonary patterns seen were mixture of at least two patterns. The presence of both alveolar and bronchial patterns was the most common findings in adult and senior dogs. Bronchial pattern was described as having the characteristic circular opacities with lucent centers.

According to Dennis (2008), radiographic identification of one or more lung pattern was due to the close anatomical relationship between different tissues in the lungs and the pathophysiology of diseases. Senior dogs commonly develop various pulmonary disorders. During this stage of life, the dogs are more susceptible to various diseases such as cardiovascular, respiratory and neoplastic diseases as a result of aging. The most common changes that appear on thorax with aging includes increased lung opacity due to increased interstitial and bronchial patterns due to mineralization of bronchial walls, the pulmonary fibrosis, mineralized cartilages and costochondral junctions, spondylosis.

Conclusion

The details of the cardiac silhouette are observed in all the views and the right arial enlargement is the most common feature. Radiography of thorax with dorsoventral view than ventrodorsal view is comfortable as the animals were geriatric and suffer from respiratory distress. Dorsoventral view provide the details of cardiac silhouette and pulmonary lobar vessels clearly than other views. Two lateral views and dorsoventral views will give majority of the details about the cardio pulmonary organs when the geriatric dogs are radiographed.

Acknowledgements: The authors are thankful to the authorities of Sri Venkateswara Veterinary University, Tirupati for providing necessary facilities to conduct this work.

References

- [1] Bahr, R.J. 2007, heart and pulmonary vessels in Thrall textbook of veterinary diagnostic radiology 5th editionst Louis mosanders Elsevier, page no 568-590.
- [2] Brinkman, E.L., Biller, D. and Armbrust, L. 2006, The clinical usefulness of the ventrodorsal versus dorsoventral thoracic radiograph in dogs *Journal of American Animal Hospital Association*, 42; 440-449.

- [3] Burk, R.L. and Feeney, D.A. 2003 *Small Animal Radiology and Ultrasonography* A diagnostic atlas and text 3rd ed. Missouri, USA: WB Saunders 25-248.
- [4] Dennis, R. 2008. Radiological assessment of lung disease in small animals alveolar, interstitial and mixed lung pattern. *In Practice* 30: 262-270.
- [5] Fox, P.R. 2007 Approach to the coughing and dyspneic dog in *Proceedings of the WSAVA*, Sydney, Australia, 20-24, pp. 1-5.
- [6] Gugjoo, M.B., Saxena, A.C., Hoque, M., Mahendran, K. and Zama, M.M.S. 2014 pericardial effusion in Labrador retriever dog *Asian Journal of Animal sciences* 8(1); 34 -37.
- [7] Guglielmini, C. 2003 Cardiovascular diseases in the ageing dogs diagnostic and therapeutic problems *Vet Res Commun Supplement* 27 555.
- [8] Kealy, J.K. and McAllister, H. 2000 *Diagnostic Radiology Ultrasonography of the Dog and Cat* 3rd edition USA: WB. Saunders Company 173-296.
- [9] Kealy, J.K. and McAllister, H. 2005 *Diagnostic Radiology Ultrasonography of the Dog and Cat* 4th edition 173-296.
- [10] Kibar M and Alkan Z 2005 Evaluation of radiographical echo cardiographical and color Doppler findings of heart disease in geriatric dogs *Turkish Journal of Veterinary Animal Science* 29; 677-684.
- [11] Lamb, C.R. and Boswood, A. 2002 Role of survey radiography in diagnosing canine cardiac disease *compendium continue educational practical* 24; 316-326.
- [12] Lehmkuhld, L.B., Bonagurad, J.D., Biller, D.S. and Hartman, W.M. 1997 Radiographic evaluation of caudal vena cava size in dogs *Veterinary Radiology & Ultrasound* 38 (2);94-100.
- [13] Mantis, P., Lamb, C.R. and Boswood, A. 1998 Assessment of the accuracy of thoracic radiography in the diagnosis of canine chronic bronchitis *Journal of Small Animal Practical* 39 518-520.
- [14] Mellanby R J Villiers E and Herrtage M E 2002 Canine pleural and mediastinal effusion a retrospective study of 81 cases *Journal of Small Animal Practice* 43; 447-451.
- [15] Rudolf H, Taeymans O, Johnson V 2008 Basics of thoracic radiography and radiology. In Schwarz T, Johnson V Eds. *BSAVA manual of canine and feline thoracic imaging*, BSAVA, 1-20.
- [16] Oyama, M.A. 2011 Canine Heart Failure - Early Diagnosis, Prompt Treatment. *NAVC Clinician's Brief* 9 (5) Retrieved from http://repository.upenn.edu/vet_papers/3.

[17] Suter, P.F. and Lord, P.F. 1974. Radiographic differentiation of disseminated pulmonary parenchymal disease in dogs and cats *The Veterinary clinics of North America* 4 687-710.

[18] Wisner, E.R. 2009 Developmental cardiopulmonary disorders of the dogs and cat In “proceedings of the 64th International SCIVAC congress held at Rimini Italy.

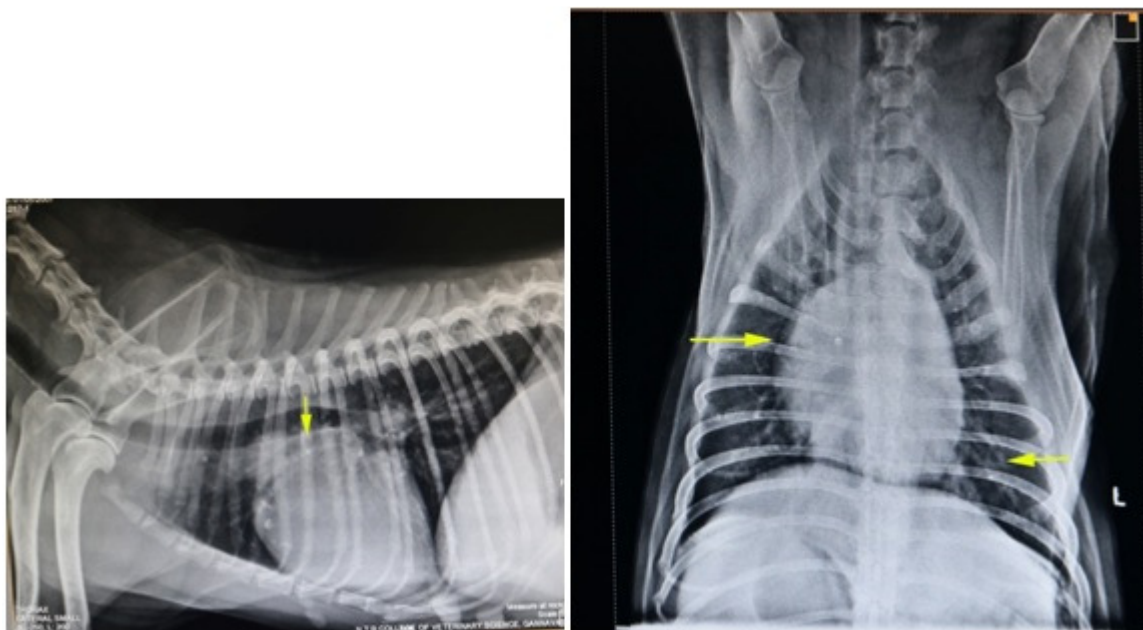


Fig 1: skiagram of right lateral view showing atrial enlargement in a dog

Fig 2: skiagram of Dorsoventral view showing right atrial enlargement (right arrow) and caudal lobar arteries (left arrow) in a dog