

## AN OUT-BREAK OF CUTANEOUS FORM OF AVIAN POX IN PIGEONS (*COLUMBIA LIVIA*)

Hemanth I, Amaravathi P, Sasidhar Babu N, Anand Kumar A\* and Sailaja N

Department of Veterinary Pathology, College of Veterinary Science, Proddatur - 516360

E-mail: aakumar7@gmail.com (\*Corresponding Author)

**Abstract:** Among the various viral infections, avian pox is one of the most common and infectious diseases encountered in both domestic and wild bird species; clinically manifesting both cutaneous and diphtheritic forms. Pox infections are usually characterised by the development of intra-cytoplasmic inclusion bodies called Bollinger bodies that contain elementary bodies called Borrelbodies. Three pigeon carcasses from Rameswaram village, Kadapa district, Andhra Pradesh, were submitted to the Department of Veterinary Pathology, College of Veterinary Science, Proddatur with a history of death of pigeons in a flock of 40 birds since 20 days. Grossly, the lesions were round, nodular, greyish white eruptions around the eye, on the beak, skin, legs and around the cloaca. Histopathological examination of the lesions revealed epithelial necrosis with infiltration of inflammatory cells, epidermal hyperplasia and hydropic degeneration of epithelial cells with large intra-cytoplasmic inclusion bodies. Both the gross and histological findings have confirmed it as a case of cutaneous form of pox infection in pigeons.

**Keywords:** Epithelial necrosis, hydropic degeneration, inclusion bodies, inflammatory cells, Pigeon pox.

### Introduction

Pox infections in avian are the most common viral infectious diseases encountered both in domestic and in about 60 wild bird species including pigeons (*Columbia livia*) (Joshi *et al.*, 2012). It is caused by double-stranded DNA virus called avian pox virus belonging to the genus *Avipoxvirus* under the family *Poxviridae*. Pox infections are usually characterised by the development of intra-cytoplasmic inclusion bodies called Bollinger bodies that contain elementary bodies called Borrel bodies (Murphy *et al.*, 1999). Clinically, avian pox infections manifest mostly in two forms: cutaneous and diphtheritic forms (Khan *et al.*, 2009). Cutaneous or dry form is characterised by nodular lesions on feather free areas of skin such as legs, beak and eye-lids, while diphtheritic or wet form is characterised by the involvement of digestive and upper respiratory tracts (Ritchie, 1995). In both forms, gross lesions consist

---

Received June 23, 2014 \* Published August 2, 2014 \* [www.ijset.net](http://www.ijset.net)

of small vesicles that progress further to nodules and finally scab formation. Mortality is generally low with the cutaneous form of disease. Apart from this, avianpox viruses are even suspected of having oncogenic properties (Bolteet *al.*, 1999). Diagnosis is usually accomplished by the clinical presentation and the lesions. However, histopathological evaluation of the lesions and demonstration of eosinophilic inclusion bodies called Bollinger bodies remains a confirmatory diagnostic tool. In the present study, an outbreak of pox infection in pigeons was reported in a flock from nearby village of Proddatur.

### **Materials and Methods**

Three pigeon carcasses were submitted to the Dept. of Veterinary Pathology, College of Veterinary Science – Proddatur from Rameswaram village, Kadapa district, Andhra Pradesh with a reported history of 20% deaths in a pigeon flock of 40 birds since 20 days by exhibiting symptoms of anorexia, depression and weakness. The carcasses were examined thoroughly and detailed post-mortem was conducted. Gross abnormalities if any were noted. Representative tissue samples were collected in 10% neutral buffered formalin and then subjected to regular histological processing consisting of dehydration, clearing and paraffin embedding steps, followed by microtomy tissue sectioning and routine Haematoxylin and Eosin staining (Luna, 1968).

### **Results and Discussion**

Upon gross examination, all the carcasses were found to be poor, emaciated and revealed small, focal, nodular greyish white lesions on the beak, around the eyes (Fig. 1), on the abdomen and on the limbs. Similar observations were reported earlier in pigeons (Mohan and Fernandez, 2008). These lesions were more severe and coalescing around the cloaca (Fig. 2). However, internally the upper respiratory and digestive tracts did not reveal any lesions of pathological significance. Based on the gross lesions, it was suspected as cutaneous avian pox.

Histologically, nodular lesions on the skin revealed areas of necrosis with infiltrating inflammatory cells. Hydrophic degeneration of epidermal cells characterised by vacuolation of the cytoplasm was observed (Fig. 3). This is in accordance with the earlier reports on avian pox (Pledger, 2005). Epidermal hyperplasia was evident. This could be due to the localised production of vaccinia growth factor (VGF) that binds to the epidermal growth factor receptors of epithelial cells and brings about hyperplastic changes (Moss, 1990). Large, round, intra-cytoplasmic eosinophilic inclusion bodies were found within the epithelial cells that have compressed the nucleus to the periphery (Fig. 4). These cytoplasmic bodies are

called as Bollinger bodies, which are believed to be the sites of viral particle replication (Murphy *et al.*, 1999). Although clinical observation of gross lesions are suggestive of pox infection in birds, histopathological examination of the lesions and demonstration of inclusion bodies is often considered as confirmatory in the diagnosis of avian pox viral infections (Pledger, 2005). Though cutaneous form of avian pox infections doesn't cause mortality, they can reduce the viability of birds by interfering with their normal vision and feeding and by predisposing the birds to further secondary bacterial infections (Reece, 1989).

### Conclusion

Based on the gross, characteristic and pathognomonic histological observations, this was diagnosed as a case of cutaneous form of avian pox in pigeons. However, the cause of death could be inanition.

### References

- [1] Bolte AL, Meurer J, Kaleta EF (1999). Avian host spectrum of avipoxviruses. *Avian Pathol* 28: 415–432.
- [2] Joshi S, Mudasir M, Sharma D, Singh R (2012). Histopathological study of cutaneous form of Avipoxvirus infection in Jungle crow (*Corvus macrorhynchos*). *Vet World* 5(10): 628-630.
- [3] Khan A, Yousaf A, Khan MZ, Siddique M, Gul ST, Mahmood F (2009). Cutaneous form of pox infection among captive peafowl (*Pavocristatus*) chicks. *Avian Pathol.* 38(1):65-70. doi: 10.1080/03079450802638061.
- [4] Luna LG (1968) Manual of histologic staining methods of the Armed Forces Institute of Pathology, pp. 32-46, Mc Graw Hill, New York.
- [5] Medina FM, Ramirez GA, Hernández A (2004). Avian pox in white-tailed Laurel-pigeons from the Canary Islands. *J Wildl Dis* 40: 351-355.
- [6] Mohan M, Fernandez TF (2008). A case report of Pigeon Pox-Histopathologic Diagnosis. *Vet World* 1(4): 117-118.
- [7] Moss B (1990). Poxviridae and their replication. In: Fields BN, Knipe DM, Chanock RM, Hirsch MS, Melnick JL, Monath TP, Roizman B., Eds. *Virology*. 2nd ed., Raven Press, New York, 2079-2111.
- [8] Murphy FA, Gibbs EPJ, Horzinek MC, Studerrt MJ (1999). *Veterinary Virology (Text Book)*, Third edition. Academic Press. Page No. 277-292.

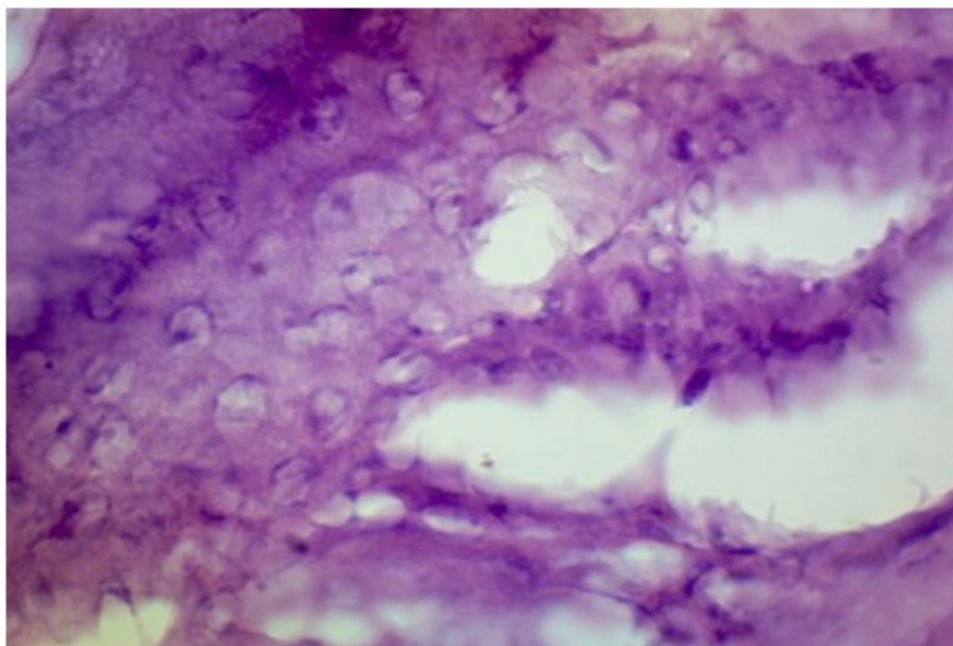
- [9] Reece RL (1989). Avian pathogens: Their biology and methods of spread. *In: Textbook of Disease and threatened birds*, Cooper J.E. ICBP technical publication 10. International Council for Bird Preservation, Cambridge, UK, p. 1.
- [10] Ritchie BW (1995). Avian viruses: Function and control. Lake Worth, Florida: Winger's Publishers: 285–311.



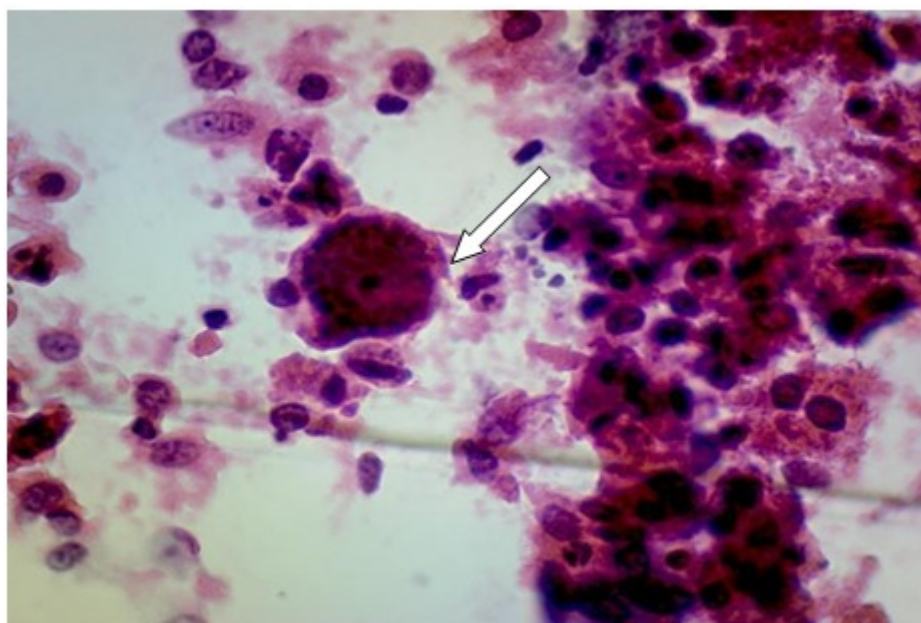
**Fig. 1:** Grayish white nodular lesions on Beak and around eyes.



**Fig. 2:** Grayish white coalescing nodular lesions around the cloaca.



**Fig. 3:** Section of skin showing hydrophic degeneration in epithelial cells of epidermis. H & E: x1000



**Fig. 4:** Section of skin showing intracytoplasmic inclusions (arrow) in the epithelial cells of epidermis. H & E: x1000