

Case Report

**25 YEARS LONGEVITY OF IONESCU-SHILEY BIOPROSTHESIS
AND HAEMOLYTIC ANEMIA**

***Ayegnon Kouakou Gregoire, MD, Mirza Alain, MD, Bergoend Eric, MD and Neville Paul, MD**

Heart Center Hospital, University of Tours
Hospital Trousseau, France

E-mail: ayekouakougreg@yahoo.fr (**Corresponding Author*)

Abstract: Haemolytic anemia is a rare complication of Ionescu-Shiley bioprosthesis which occurred particularly in the first decade following the mitral valve replacement. We report here a case of a 75 year –old man who underwent to an isolated mitral valve replacement for severe Barlow disease using Ionescu-Shiley bioprosthesis. After 25 years of exceptional longevity, a dysfunction of the Ionescu-Shiley bioprosthesis was revealed in mitral position by an Haemolytic anemia.

Keywords: Longevity; haemolytic anemia; Ionescu-Shiley bioprosthesis.

Introduction

In 1978, Ionescu MI and coworkers [1] reported many advantages of Ionescu-Shiley bioprosthesis (ISB) according to its best hemodynamic and durability without lifely oral anticoagulation. Since this period, controversies subsisted. In literature, the haemolytic anaemia (HA) and bioprotheses valves structural dysfunctions were rare reported for long-term follow up.

The present report describes a moderated dysfunction in the mitral valve position of the ISB revealed by an HA which lead to redux valve 25 years later.

Case report

A 75-year-old man with Barlow disease presented initially at the age of 50 years with severe mitral regurgitation secondary to ruptured chordae of the posterior cusp and prolapsed of the anterior cusp. This man had had pulmonary tuberculosis with restrictive pulmonary insufficiency. The mitral valve was replaced by a 29 mm ISB. He was discharged seven days after the initial operation without complications. During the follow-up, he was hemodynamically stable, but in 1991 he had a left eye amaurosis while he was in sinus rhythm.

25 years later, the HA was at the escalation progress associated to the dyspnoea NYHA type III from the few months before. The Physical examination showed signs of predominant mitral insufficiency with an important jaundice. Blood analysis showed haemoglobin level at 78 g/l (normally 140 +/- 20), reticulocyte 10 % of erythrocyte (5% when corrected for the erythrocyte count), schizocyte 15% of reticulocyte count (4% when corrected for the reticulocyte count) and serum bilirubin 16 mmol/L (Normally 0 to 4). The results of the Combs test were negative and the creatinine was 127 (Normally 100 +/- 30) umol/L. Rapid transfusion of volume (7 units of blood) allowed improvement in the patient's hemodynamic and kept pace of haemolysis. An electrocardiogram confirmed sinus rhythm and left atrial (LA) enlargement. Transoesophageal two dimensions echocardiography showed a dilated LA (LA systolic diameter 56 cm), intra prosthetic leakage grade II and a good systolic left ventricular function without bioprosthetic calcification (Fig.1). At the cardiac catheterisation, there was a gradient of 10 mmHg across mitral valve and a pulmonary artery pressure of 48/25 mmHg. Coronary angiography confirmed good left ventricular function (ejection fraction 66 %) and normal coronary arteries. Preoperative check up exam was normal. In November 2008 (one week after admission), ISB was explanted (Fig.2) and replaced by a 29 mm Carpentier- Edwards's pericardial prosthesis (Perimount) in the mitral position. Intra operatively, the frees cusps areas were rigid and the prosthetic cusp adjacent till posteromedial commissural area was calcified (Fig.3). But cusps were not teared. We observed a well-grown neointima over the Dacron recovered frame of the inner surface. The implantation of the Carpentier- Edwards's bioprosthesis was performed using an interrupted simple suture with ethibond 2/0 on cardiopulmonary bypass. Postoperatively the patient was transfused for anemia with two packs of red blood cells. He went to the ICU hemodynamically stable in sinus rhythm with atrioventricular bloc Ist grade. In addition, the Transoesophageal two dimensions echocardiography control showed normal motion of the new bioprosthesis without leakage; in this while the mean trans-bioprosthetic mitral valve gradient was 6 mm Hg. At day 9, the blood analyses showed an haemoglobin level at 112 g/L, the creatinine was 98 umol/L and the serum bilirubin was 12 mmol/L. He subsequently made an uneventful recovery and discharged from the hospital 2 weeks after re-operation. His medication at time of discharge included enoxaparine, diuretic (aldactone), iron and folate supplement. Five years later, the patient is alive and doing well. Now he has a New York Heart Association class I and his heart rhythm is still sinus. Clinical examinations don't show any signs of HA.

Discussion:

Firstly, Myers and coworkers [2] reported the development of an isolated HA in a patient who had had the mitral valve replaced with a porcine valve. The anemia was transient and disappeared completely after 4 months with normal bioprosthetic motion valve. The authors hypothesized that the haemolysis was secondary to erythrocyte trauma caused by the prosthetic design. Regarding the precedent argument, the Dacron-covered ring and stent of an ISB were ameliorated. But HA associated with an ISB in mitral position has been currently reported [1, 3, 4]. These cases suggested that the contemporary risks of HA after ISB in mitral position are not well known. Certainly HA never occurred so late after our previous implantation of bioprosthesis valve. Piquemal R and coworkers [5] reported two cases. Their two patients had ISB deterioration and subclinical HA which had occurred in the 10th respectively 12th year after the mitral valve replacement. Both had their bioprosthesis replaced for stopping an HA even if the ISB was not too calcified. The authors concluded that HA lead to premature redux valve replacement. In contrary, Reddy SB and coworkers [3] didn't replace the ISB inserted in the mitral position two weeks before haemolytic anemia occurred because the prosthetic valve hadn't had any dysfunction. But postoperatively, their attitude necessitated an iterative transfusion and readmission during 12 months before the anemia disappears completely. In each of these cases, however the degree of haemolysis and the time it's appears; anemia disappears gradually and completely. So the emergency of the re-intervention depends of the advanced bioprosthetic valve damage and the degree of HA. It wasn't the case when using Ionescu-Shiley mechanic valve [3]. As Reddy SB and coworkers we don't find the cause of haemolysis considering our intraoperative aspect and morphology of the excised bioprosthesis (Fig.2, 3). To our knowledge, our report is unique and has the exception to prove that an HA which revealed the ISB valve structural's dysfunction in mitral position appears 25 years later. The longevity of this ISB is not well known. Patient was young (50 year-old) when ISB was inserted due to contraindications for oral anticoagulation. His young age is likely benefit for our patient. It is reported to be a major determinant of the valve failure which is largely due to the calcification occurred between 60 and 70 years [4]. This longevity was reported by Watanabe Y and coworkers [6]. The authors explained this longevity of ISB without HA by an absence of cusps tears and well-grown neointima over the Dacron cloth of the inner surface. But their patient presented severe calcification which obstructed ISB. They didn't observe an HA although a severe calcification of ISB. Butany JW and coworkers [7] observed the same macroscopic aspect on explanted ISB 20 years after

the implantation. The authors hypothesized that the excessive pannus growth may likely protect the valve from earlier failure. From 1970 to 1980, basing on the reported deterioration rate of pericardial bioprostheses in the mitral position, ISB as Hancock pericardial have been prudentially restricted for elderly [8]. The main reason of these restrictions were frequent a paraprosthetic leak observed with Hancock pericardial and the premature tears known of ISB associated to calcification which is compromising the long term durability. For the authors, using both types of pericardial bioprostheses for the oldest patients may drop the risk of the re-intervention. After ISB, Hancock II (which is Hancock Standard ameliorated for thrombogenicity) has been abandoned quickly in 1980 for the tears. More recently controversies subsisted. Butany JW and Watanabe Y reported 20 years respectively 24 years of ISB insertion in the mitral position without paraprosthetic leak or tears in none degenerative previous valvulopathy . Regarding these cases, we should deplore that ISB had had more quality that was not well exploited. Unfortunately, it was accused to be responsible of HA.

Conclusion: This case shows that the knowledge on greater durability, longevity and long term outcome of patients is still incomplete when ISB is in a mitral position. In this position, ISB is subjected to a regular hemodynamics stress which can compromise its longevity. However, ISB may have an extreme longevity due to excessive pannus growth without early damage and without an haemolytic anemia before 25 years. So, the HA must be considered owes as a symptom of the discovery of the ISB's latest dysfunctions.

References

- [1] Ionescu MI, Tandon AP. Long term clinical and hemodynamic evaluation of the Ionescu-Shiley pericardial xenograft heart valve. *Thorax chir Vask Chir* 1978; 26 (4): 250 - 8.
- [2] Myers TJ, Hild DH, Rinaldi MJ. Hemolytic anemia associated with heterograft replacement of the mitral valve. *J Thorac Cardiovasc Surg* 1978; 76: 214 - 215.
- [3] Reddy SB, Pater JL, Pym J, Armstrong PW. Hemolytic anemia following insertion of Ionescu-Shiley mitral valve bioprosthesis. *Can Med Assoc J* 1984; 131 (12): 1469 - 70.
- [4] Doenst T, Borger MA, David TE. Long-term results of bioprosthetic mitral valve replacement: the pericardial perspective. *J Cardiovasc Surg* 2004; 45 (5): 449 - 54.
- [5] Piquemal R, Fauchier L, Regimbeau C, Babuty D, Neville P, Renard JP. Late-occurrence hemolytic anemia after mitral valve bioprosthesis: 2 cases. *Arch Mal Coeur Vaiss* 1998; 91 (7): 879 - 81.

[6] Watanabe Y, Ohkawa S, Yamabuki K, Tsuneoka H, Sugiyama N, Hiyama T. A case 24 years longevity of an Ionescu-Shiley bioprosthesis in the mitral position. *Asian Cardiovasc Thorac Ann* 2006; 14 (5): 96 - 8.

[7] Butany JW, Kesarwani R, Yau TM, Singh G, Thangaroopan M, Nair V, Leong SW. The role of pannus in the longevity of an Ionescu-Shiley pericardial bioprosthesis. *J Card Surg* 2006; 21 (5): 505 - 7.

[8] Valfre C, Rizzoli G, Zussa C, Lus P, Polesel E, Mirone S, Bottio T, Gerosa G. Clinical results of Hancock II versus Hancock Standard at long-term follow-up. *J Thorac Cardiovasc Surg* 2006; 132: 595 - 601.

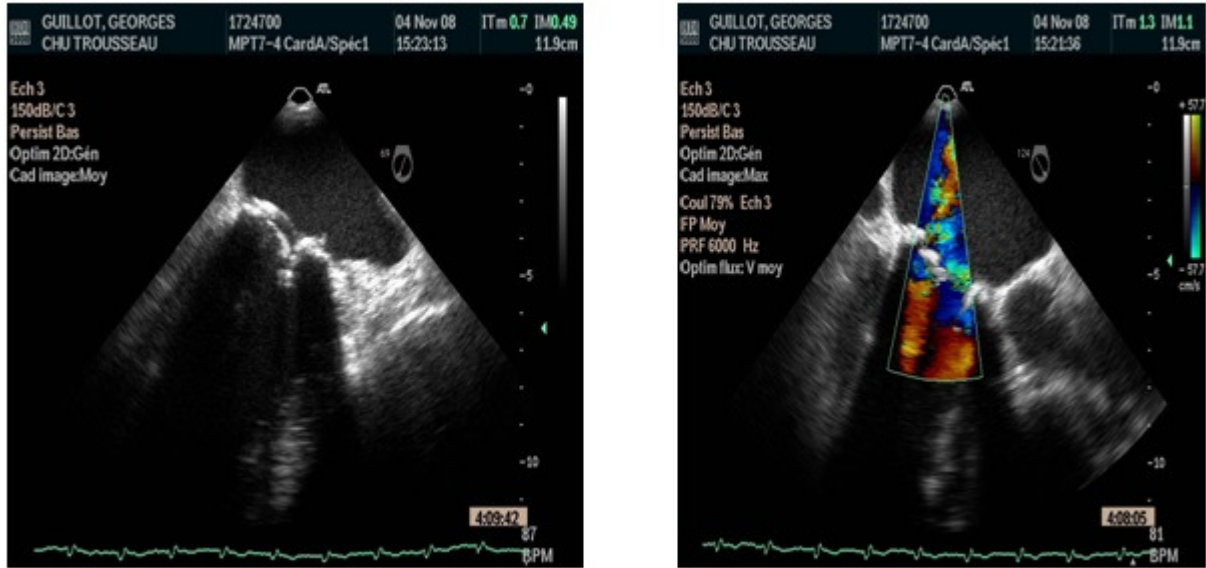


Fig. 1 Preoperative Transesophageal two dimensions echocardiography and Doppler showed absence of tears; good cooptation leaflets; intraprosthetic valve regurgitation Grade II without calcification.

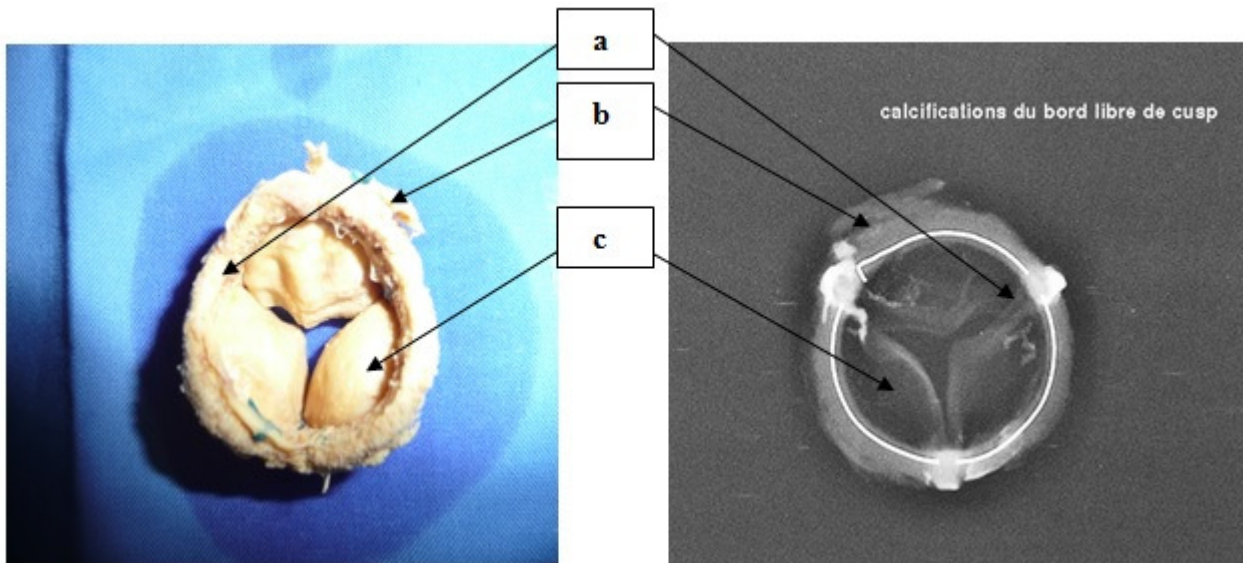


Fig.2: Picture of excised Ionescu-Shiley pericardial valve;

Fig.3: Excised IS pericardial valve X- ray film.

Postoperative picture (Fig.2) and x ray film (Fig.3) showed: (a) posteromedial commissural area calcification; (b) excessive pannus growth (arrow); (c) free cusps areas rigid and calcified.