

## **SURGICAL MANAGEMENT OF CHERRY EYE IN ROTTWEILER DOG**

**A. Rais<sup>1</sup>, \*L.N. Sankhala<sup>2</sup>, R.K. Saini<sup>1</sup> A. Shringi<sup>1</sup> and Mukesh Gahlot<sup>3</sup>**

<sup>1</sup>Veterinary Officer, Govt Veterinary Hospital, Rajasthan

<sup>2</sup> Assistant Professor, Department of Pharmacology and Toxicology, College of Veterinary  
and Animal Science, RAJUVAS, Bikaner-334001

<sup>3</sup>PhD scholar, Department of Surgery and Radiology, College of Veterinary and Animal  
Science, RAJUVAS, Bikaner-334001

E-mail: allensankhala@gmail.com (\*Corresponding Author)

**Abstract:** A three year old Rottweiler male presented with history of round red colour mass from medial canthus of right eye from last 15 days. After complete clinical examination, the condition was diagnosed as cherry eye (Prolapse of the third eyelid gland). After surgical correction, dog was recovered uneventfully.

**Keywords:** Eyelid, Cherry eye.

### **INTRODUCTION**

Most animals have a third eyelid except monkeys, snakes and most of the fish. The third eyelid or nictitating membrane is a structure located in the inside corner of the eye. The functions of the third eyelid are to protect the eye and distribute the tear film. Cherry eye is a common term for prolapse of the third eyelid gland also referred to as “haws. Cherry eye is a common ophthalmic problem of dogs and rarely of cats. The condition can occur in one or both eyes. Breeds especially Bulldog, Pekingese, Cocker Spaniel, Neapolitan Mastiff, Beagle and Basset Hound are more prone to this pathological syndrome (Herrera, 2005; Moore, 1998). The cause of the cherry eye is unclear (Dugan *et al.*, 1992; Martin, 2009). However, it is believed that it may occur secondary to inflammation and a weakness in the connective tissue attaching the gland to its normal position posterior and ventral to the nictitans, allowing the gland to migrate dorsally and flip up to protrude above the leading margin of the membrane (Morgan *et al.*, 1993; Dugan *et al.*, 1992).

### **HISTORY AND DIAGNOSIS**

A three year old Rottweiler male presented with history of round red colour mass from medial canthus of right eye from last 15 days. Owner said that dog was producing more tears

and feeling uncomfortable. On clinical examination of eye, prolapsed mass was congested, ocular discharge, epiphora and conjunctivitis. Dog was rubbing his eye due to severe irritation and was very uncomfortable. On the basis of history and clinical observation case was diagnosed as cherry eye (Prolapsed of nictitans gland).

#### **TREATMENT**

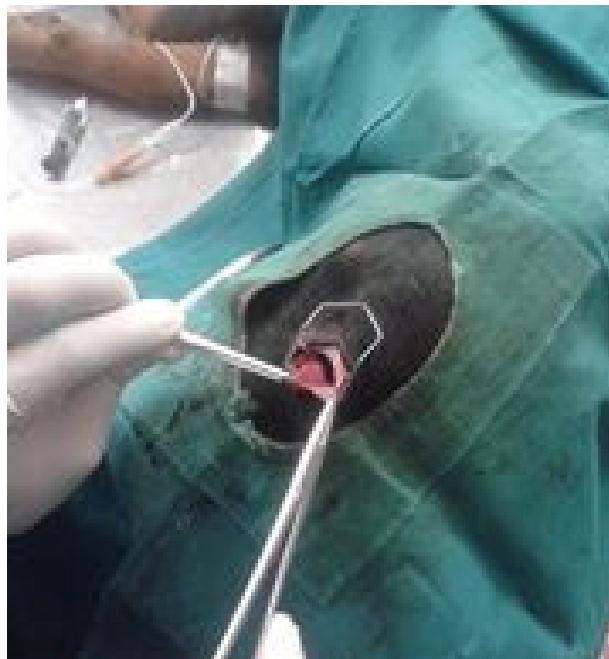
Standard preoperative preparations for surgery were followed. Pre-anaesthetic medication consisted of atropine sulfate (0.04 mg/kg) was given after 6-8 hours fasting period of dog. Anaesthesia was induced by xylazine HCl (0.5 mg/kg, IM) followed by ketamine (10 mg/kg, IM). A curved mosquito forcep was applied at the base of protused mass of third eyelid then ligated at its base by chromic cat gut 3/0. After ligation, gland was excised from its base. Anesthetic recovery and postoperative recovery following surgery was recorded. Post operatively dog was given a course of antibiotics and anti-inflammatory drugs once daily for 5 days. Owner was also advised to instill gentamycin eye drops thrice daily for 7-8 days.

#### **REFERENCES**

- Herrera D., 2005, Surgery of the Eyelids, Proceedings of the World Small Animal Veterinary Association Mexico City, Mexico, 1-4 PMID:16203008
- Moore C.P., 1998, Terceira pálpebra. In: Slatter D., Manual de cirurgia de pequenos animais, 2nd Ed., Paulo: Manole, 2: 1428-1435
- Dugan, S.J., Severin, G.A., Hungerford, L.L., Whiteley, H.E., Roberts, S.M.: Clinical and histological evaluation of the prolapsed third eyelid gland in dogs. J. Am. Vet. Med. Assoc., 1992; 201: 1861-1867.
- Martin, C.L.: Conjunctiva and third eyelid. In: Martin, C.L., Ed. Ophthalmic Disease in Veterinary Medicine. Manson Publishing Ltd., London. 2009; 183-214.8. Moore, C.P., Frappier, B.L., Linton, L.L.
- Morgan, R.V., Duddy, J.M., McClurg, K.: Prolapse of the gland of the third eyelid in dogs: a retrospective study of 89 cases (1980 to 1990). J. Am. Anim. Hosp. Assoc., 1993; 29: 56-60.



Dog with cherry eye condition



Surgical correction of eye