

SURGICAL MANAGEMENT OF LIPOMA IN A DOG

***K. Manoj Kumar¹, N. Dhana Lakshmi, P. Veena and K. Sudarshan Reddy**

Department of Veterinary Surgery & Radiology,
College of Veterinary Science, Tirupati, Andhra Pradesh, India– 517502
E-mail: manojvety12@gmail.com (**Corresponding Author*)

Abstract: An eight year old female cross bred dog was presented with history of mass at the left thigh region. Fine needle aspiration biopsy revealed large number of lipid globules along with cells. The tumour mass was excised surgically and subjected to histopathological examination confirming lipoma.

Keywords: Dog, Lipoma.

Introduction

The adipose tissue tumours are common mesenchymal skin tumours of dogs with higher incidence in old female dogs (Julie *et al.*, 2013). Lipomas are benign tumours arising from mature adipocytes. The Lipomas located between skin and muscle layers are soft and freely movable while those located between muscles have a more firm consistency and are not mobile. Being benign tumours, surgical excision is the right choice of treatment (Veena *et al.*, 2013). A case of Lipoma in a dog with its confirmatory diagnosis and surgical management is reported.

Case history and observations:

An 8 year old female crossbred dog was presented for assessment of large growth situated over left thigh (Fig. 1). The growth on thigh was first noticed about 2 month back. There was a gradual increase in size of the growth since last 10 days. On presentation, dog having growth on thigh was bright, comfortable with no signs of visible lameness. On palpation, mass was semisolid in consistency, located subcutaneously and was moving freely indicating absence of attachment to structures beneath it. The clinical parameters like heart rate, respiration rate and temperature were within physiological limits. Haematobiochemical parameters were also normal. Radiograph of thorax revealed no lung metastasis. Fine needle aspiration biopsy revealed large number of lipid globules along with cells. The case was tentatively diagnosed as Lipoma, a skin tumour and was decided to perform surgical excision of mass.

Treatment and Discussion

Dog was prepared for aseptic surgery and premedicated with Atropine sulphate @0.045 mg/kg body weight subcutaneously, followed by xylazine hydrochloride @ 1 mg/ kg body weight intramuscular and general anaesthesia was induced with propofol @ 5mg/ kg body weight intravenously. The dog was restrained in lateral recumbency. An elliptical skin incision was given and following blunt dissection, the tumorous growth was removed completely (Fig. 2) and sent for histopathological examination. To avoid anatomical dead space and accumulation of serosanguinous fluid, subcutaneous tissue was opposed with subcuticular sutures, using chromic catgut no. 0. Skin was sutured with cruciate mattress sutures using no. 1 surgical silk. Post operatively inj. Ceftriaxone @ 20 mg/ kg b.wt for 5 days and inj. Meloxicam @ 0.5 mg/ kg b.wt for 3 days were given. Antiseptic dressing of suture line with povidone iodine was advised. The animal recovered uneventfully, the sutures were removed after tenth postoperative day. Excised tumour growth was subjected to histopathological examination which revealed polyhedral closely packed cells with several vacuoles and nucleus was pushed to one side (Fig. 3).

The tumor of adipose tissue can be divided into benign (lipomas) and malignant neoplasms (liposarcomas). Although they may resemble one another macroscopically, they are histopathologically distinct (Baez *et al.*, 2004). Among these tumors, lipomas are much more common than liposarcomas (Vegad, 2012). The proximal extremity of limb and trunk are the most common site for lipomas (Goldschmidt and Hendrick, 2002). The present case was followed after surgery and there was no recurrence of tumor up to one year. The reason for non recurrence in present case might be due to its complete excision and early diagnosis as opined by Rao *et al.* (2011).

References

- [1] Baez, J.L., Hendrick, M.J., Shofer, F.S., Goldcamp, C. and Sorenmo, K.U. (2004). Liposarcomas in dogs: 56 cases (1989-2000). *Journal of American Veterinary Medical Association*, 224: 887- 91.
- [2] Goldschmidt, M.H. and Hendrick, M.J. (2002). Tumors of the skin and soft tissues. In: *Tumors of Domestic Animals*, 4th Edit., DJ Meuten, Ed., Iowa State Press, Iowa, pp. 45-117.
- [3] Julie, B., Raghavan, K.S., Jayesh, V., Swapna, S.A., Pradeep, M.A. and Sajitha, I. (2013). Surgical Management of Liposarcoma in a dog. *Indian Veterinary Journal*, 90: 97-99.
- [4] Rao, C.M., Prasad, B.C. and Krishna, N.V.V.H. (2011). Surgical Management of Lipoma in a Dog. *Veterinary World*, 4: 34.

- [5] Veena, P., Bharathi, S. and Devarathnam, J. (2013). Surgical management of lipoma in a dog. *Intas Polivet*, 14(2):475-476.
- [6] Vegad, J.L. (2012). *A Textbook of Veterinary General Pathology*. 2nd Edn, International book distributing Co. pp: 354-57.

FIGURES

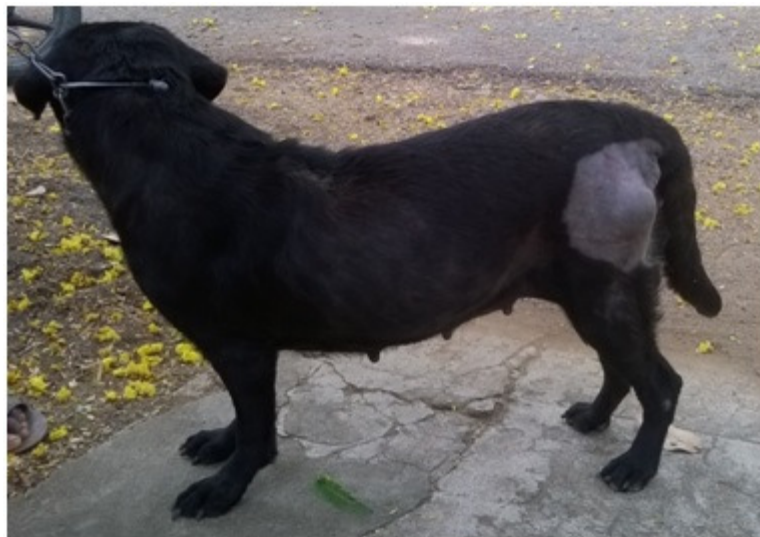

Fig: 1 semi solid tumour mass in the left thigh region

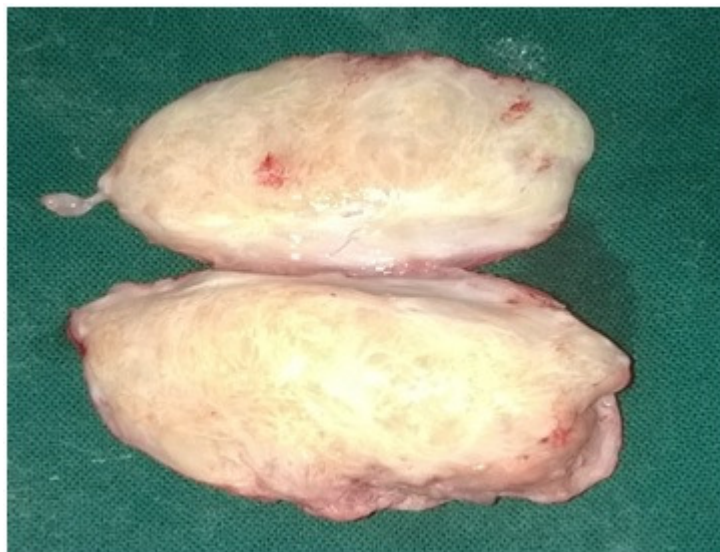

Fig: 2 Mass from thigh after removal

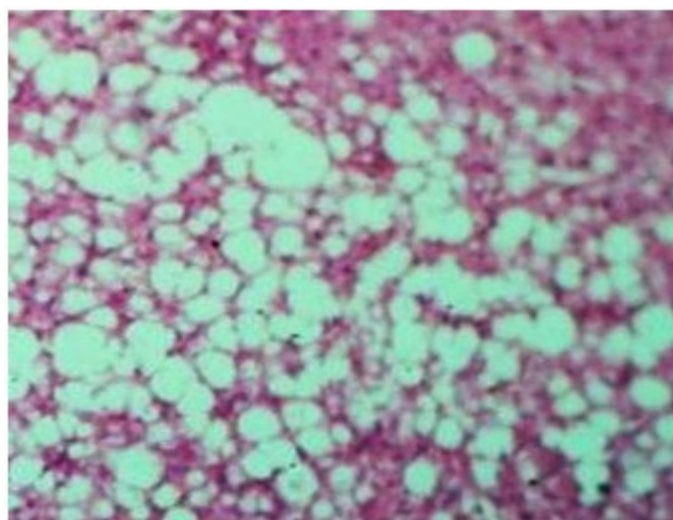


Fig: 3 Histopathological confirmation of Lipoma (H & E 70)