

COCCIDIOSIS IN A GOAT KID

**Rakesh Kumar^{1*}, Rahul Katiyar², Surender Kumar³, Venketaramireddy Balena¹,
Shailesh Kumar Patel¹, Snehil Gupta⁶, Vikas Kumar⁴ and Sourabh Kant⁵**

Division of Pathology¹, Division of Gynaecology and Obstetrics², Division of Veterinary
Medicine³, Division of Animal Nutrition⁴, Division of Physiology and Climatology⁵,
Division of Parasitology⁶, ICAR-IVRI, Izatnagar, Bareilly, Uttar Pradesh, 243122
PhD Scholars^{1, 2, 3, 4, 6}, MVSc Scholar^{4, 5}
E-mail: rakudoc@gmail.com (*Corresponding Author)

Abstract: A male goat kid died with the history of profuse diarrhoea. The necropsy examination revealed the presence of watery content in the entire GIT. The perineal area was soiled with diarrhoeic content and kid was completely emaciated. On bacterial and viral examination, the reports were negative. But the faecal and histopathological examination showed the presence of coccidian oocysts. Histopathological examination of intestine showed the loss of villi and sloughing, and presence of coccidian oocysts along with inflammatory cells.

Keywords: Goat; coccidia; oocyst.

Introduction

Gastrointestinal parasites are a serious problem for livestock industry in tropics (Varghese and Yayabu, 1985)) and most common among these are helminths and coccidian parasites (Maingi et al., 1993; Waruiru et al., 1993). Coccidiosis leads to poor growth rate, diarrhoea, dysentery and anaemia (Soulsby, 1982; Chartier and Paraud, 2012) and supposed to be one of the economically most important diseases of small ruminants (sheep and goats) as far as intensive farming is concerned (Chhabra and Pandey, 1991). Coccidiosis in small ruminants is caused by a protozoan parasite which belongs to genus *Eimeria* and often can be seen in small as well as in large intestine (Chartier and Paraud, 2012). In goats the most important species which leads to clinical signs includes *E. ninakohlyakimovae* and *E. arloingi* (Koudela and Bokova, 1998; Yvoré et al., 1985) while in sheep *E. ovinoidalis* and *E. crandallis* are more pathogenic. There is no cross infection between these two species i.e. sheep and goat (McDougald, 1979). The coccidian parasites often lead to destruction of epithelial cells of intestine and interfere with intestinal microflora as well (Mohammed et al., 2000). Coccidiosis is mainly suspected when animals are kept under poor hygienic conditions and the mortality is mainly evident during weaning period (Chartier and Paraud, 2012).

*Received Mar 23, 2016 * Published April 2, 2016 * www.ijset.net*

Material and methods

A male goat kid was submitted for post-mortem examination. Animal suffered with profuse diarrhoea since 1 week before the death and was quite weak. On external examination, the perianal area found to be soiled with foul smelling fluidly content. On internal examination, the entire GIT found to be congested. The small intestine showed the presence of fluidly content along with ulcerative areas. The abomasal part was also filled with foul smelling diarrhoeic content. The mesenteric fat showed gelatinization along with petechial haemorrhages. The mesenteric lymph nodes (MLNs) were enlarged with pulpy consistency. On cut section, MLNs showed gelatinous appearance.

Tissues collected at post-mortem examination were fixed in 10% buffered formalin and after proper fixation were embedded in paraffin according to the protocol given by Luna (1968). The tissue sections were cut into 5 micrometer thickness and were stained with H & E (Haematoxylin and Eosin stain). The blood samples were collected in di-potassium EDTA from the heart and send to bacteriology laboratory for bacterial examination. The intestinal contents on ice were send for enteric viruses examination. The faecal sample also examined for any parasitic egg/ova.

Results

All the reports for viruses and bacteria came negative, while the parasitological examination revealed the presence of coccidian oocysts in faecal sample under microscope. The parasitological examination was further supported by histopathology. The histopathological examination of intestine showed, loss of microvilli, areas of sloughing, coccidian oocysts along with inflammatory cells involving the entire intestine.

Conclusion

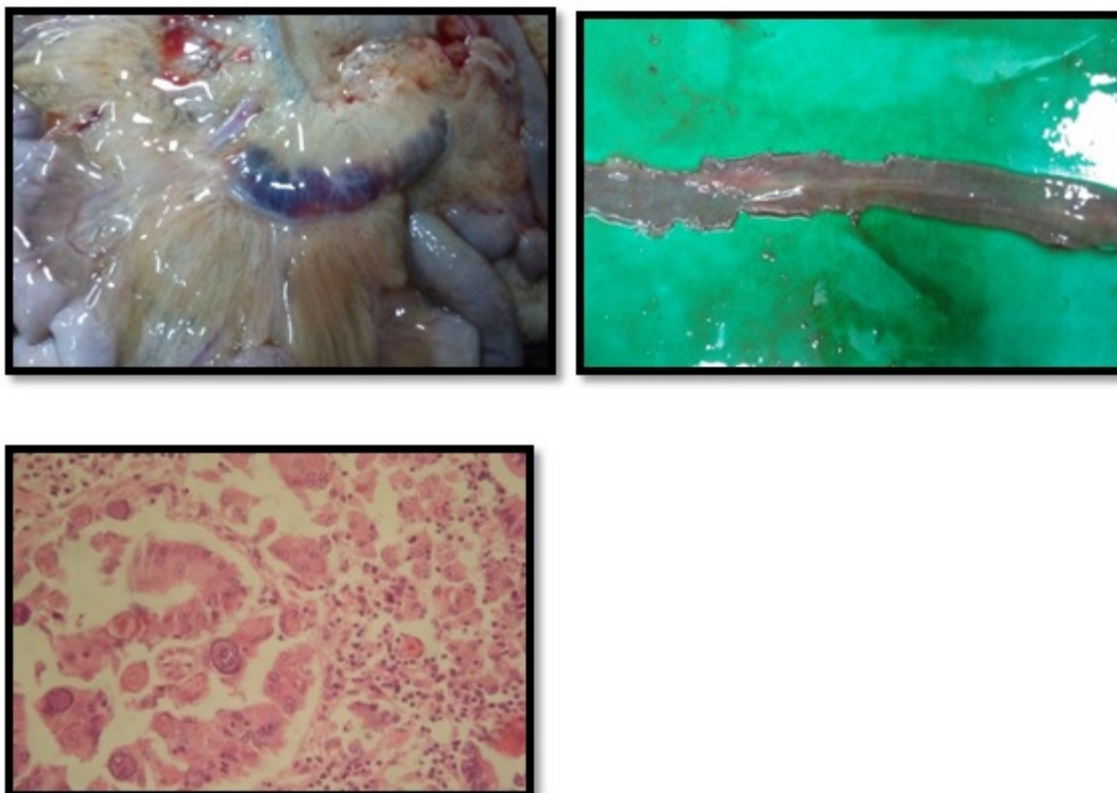
The kid was suffering from diarrhoea and was emaciated. The bacterial and viral examination also showed negative results. But the faecal examination along with histopathological examination revealed the presence of coccidian oocysts. So, the study provides an evidence for coccidiosis in goat kid. To the best of our knowledge, the animal might have ingested sporulated oocysts which on excystment led to the release of sporozoites, schizonts, merozoites and at last gametes. These gametes when came out of the enterocytes led to hemorrhagic enteritis. The hemorrhagic enteritis led to anaemia, malabsorption, diarrhoea, dehydration and ultimately death because of hypovolemic shock.

Legends

Fig. 1. Mesenteric lymph nodes highly congested and mesenteric fat shows gelatinization.

Fig. 2. The cut section of intestine shows sloughing along with fluid content.

Fig. 3. The intestine shows sloughing of villi and presence of coccidian oocysts along with inflammatory cells. H & E *100



References

- [1] Chhabra, RC and Pandey, VS. 1992. Prevalence of coccidia in sheep in Zimbabwe. *Small Rumin. Res.* 8: 257-264.
- [2] Chartier, C & Paraud, C (2012). Coccidiosis due to *Eimeria* in sheep and goats, a review. *Small Ruminant Research.* 103(1): 84-92.
- [3] Koudela, B and Bokova A. 1998. Coccidiosis in goats in the Czech Republic. *Vet. Parasitol.* 76: 261–267.
- [4] Maingi, N., Gichanga, EJ and Gichovi, VM. 1993. Prevalence of gastro-intestinal helminths and coccidial parasites and frequency distribution of some nematode genera in some farms in four districts in Kenya. *Bull. Anim. Hlth. Prod. Afr.* 41: 285-290.
- [5] McDougald, LR. 1979. Attempted cross-transmission of coccidia between sheep and goats and description of *Eimeria ovinoideal* sp. *J. Protozool.* 26: 109–113.

- [6] Mohammed, RA., Idris, OA., El Sanousi, SM., Abdelsalam, EB. 2000. The effect of coccidian infection on the gut microflora of Nubian goat kids. *Dtsch. Tierärztl. Wochenschr.* 107: 389–428.
- [7] Soulsby, E.J.L. 1982. *Helminths, Arthropods and Protozoa of Domesticated Animals*. Seventh Edition. Bailliere Tindall, London, pp. 594-606.
- [8] Varghese, T and Yayabu, R. 1985. Ovine coccidiosis in Papua New Guinea. *Vet. Parasitol.*, 39: 181-191.
- [9] Waruiru, RM, Mbutia, PG and Kimoro, CO. 1993. Prevalence of gas&o-intestinal parasites and liverflukes in calves in Mathira Division of Nyeri District, Kenya. *Bull. Anim. Hlth. Prod. Afr.* 41: 291-296.
- [10] Yvoré, P., Esnault, A., Naciri, M. 1985. La coccidiose caprine. Effets de contaminations mono ou multispécifiques. *Rec. Méd. Vét.* 161: 347–351.
- [11] Luna LG. 1968. *Manual of Histologic Staining Methods of the Armed Forces Institute of Pathology*, 3rd ed. McGraw-Hill, New York.