

*Case Report*

**MANAGEMENT OF TRAUMATIC OCULAR PROPTOSIS IN CAT**

**\*Anoop Kumar<sup>1</sup>, R.R. Rohi<sup>2</sup>, Pooja Pawar and Pravesh Kumar**

Department of Teaching Veterinary Clinical Complex,  
Mumbai Veterinary College, Goregaon, Mumbai-400065

<sup>1</sup>M.V.Sc. Scholar and Dept. of Gynaecology and Obstetrics, Orissa Veterinary College

<sup>2</sup>Assistant professor, Dept. of veterinary surgery and radiology

E-mail: anoopy4@gmail.com (\*Corresponding Author)

**Abstract:** A cat presented in TVCC Goregaon, Mumbai with a history of injury on neck region, swelling head region and blindness. Clinical examination revealed pain around eye region, corneal ulceration and mild prolapse of globe. So temporary tarsorrhaphy was done of traumaticocular proptosis.

**INTRODUCTION**

Traumatic proptosis may follow blunt trauma (e.g., being hit by a car, fight with another animal). Secondary orbital hemorrhage and swelling displace the globe further from the orbit. Proptosis is displacement of the eye ball out of the eye socket so that the eyelids are trapped behind the globe. It is common in dogs and infrequent in cats. In cats, proptosis usually results from severe trauma to the head; often, other facial bones are fractured. In cats and in other types of dogs, blunt trauma, as from an automobile accident or being kicked by a horse, is a more common cause. The most common cause of proptosis in small breed is a fight with a larger breed. In a cat fight the larger cat tends to grab the small cat by the scruff of the neck. Pulling the skin back over the head allows the eyes to pop forward. Hence the present study was planned communication puts on a record of chronic case of traumatic proptosis managed successfully by tarsorrhaphy technique in a non-descript cat.

**History and Finding**

A seven month old female cat presented in TVCC Goregaon Mumbai with history of injury, swelling region and eye blindness. Owner reported that cat was accident by motorcycle last month when the mandible was fractured, but now the owner had not witnessed the trauma; however, they had heard a scuffle and thought that the patient may have had a fight with the household cat. On examination, the right eye was proptosed with a miotic pupil. There was

---

*Received April 22, 2016 \* Published June 2, 2016 \* [www.ijset.net](http://www.ijset.net)*

no direct or consensual pupillary light reflex. There was unilateral Traumatic proptosis absence of menace and pupillary light reflex (PLR). Anamnesis revealed that the cat suffered traumatic injury to eyeball due to infighting with another male at owner's residence 9 days back leading to protrusion of eyeball. The options for therapy including reduction of the globe with a temporary tarsorrhaphy or enucleation were discussed with the owner. The prognosis for vision recovery was poor; however, retaining the globe with tarsorrhaphy was an option for cosmetic reasons.

### **Treatment**

The proptosed globe was cleaned with gauze pads soaked in normal saline. The animal was administered with 50 ml DNS and broad spectrum antibiotics ceftriaxone @ 20 mg/ kg followed by premedication with atropine sulphate @ 0.04 mg/kg body wt. SC. Anesthesia was induced with a combination of xylazine hydrochloride @ 1 mg/ kg body wt. IM followed 10 minutes later by ketamine hydrochloride @ 10 mg/kg body wt. IM. Aseptically preparation of periorbital skin and eyelids by clipping the periorbital area and irrigating the periorbital tissues and globe with normal saline was carried out in routine manner prior to surgery. A cat was placed in under anesthesia, and the eye was replaced in the socket, then an incision was made in the outer edge of the eye lid to allow more space for the eye to be replaced in to the bony socket, and the external eyelids was temporarily closed with sutures (temporary tarsorrhaphy). In temporary tarsorrhaphy was performed with horizontal mattress suture pattern. A small gap at the lateral or medial canthus was left for administration of topical ophthalmic medications. Post-operative care with topical antibiotics and atropine were administered through the eyelid to help decrease the cat's pain and aid in healing of the cornea. Sutures were removed after 12 days and there was uneventful recovery, but the cat could not regain its vision.

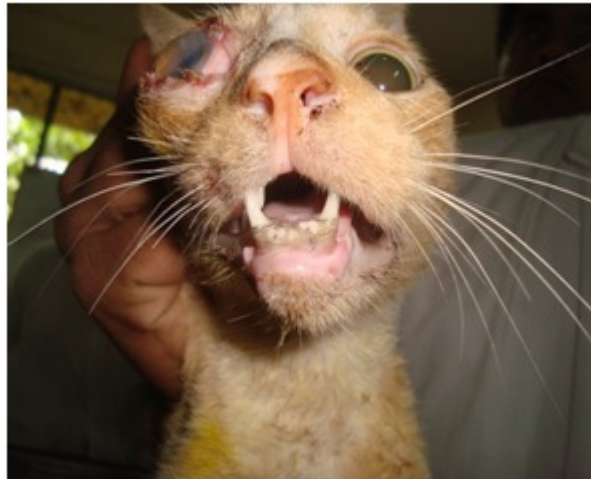
### **Discussion**

The present study revealed that cat was suffered from unilateral Traumatic proptosis .Traumatic proptosis can occur in any breed and in both dogs and cats (Gilger B.C, et al.1995). The ocular emergencies like proptosis/forward displacement of globe can be treated with enucleation or replacement with tarsorrhaphy depending on the viability of the extra ocular tissues and eye (Mandell, 2005). In the present case the extraocular musculature was enough to hinder the replacement of globe behind the lids. However (Ofri 2008) reported presence of PLR reflex to be the important sign for prognosis; in cat and dogs, but in this case absence of PLR in right eye indicated a poor prognosis. Persians are more prone to traumatic

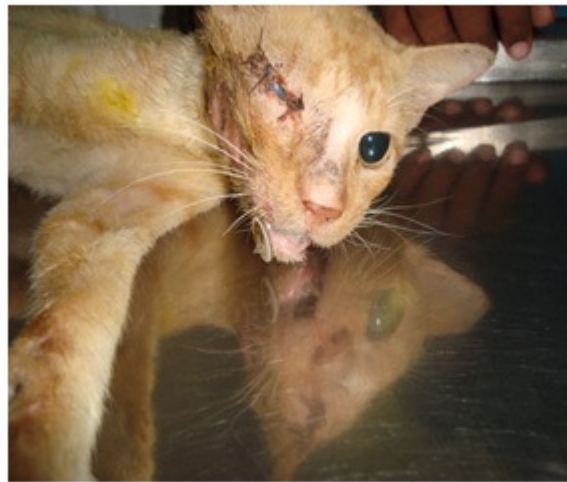proptoses, due to their flatter facial structure and shallow eye sockets, the condition can occur in any breed of cat. Bleeding of the interior eye or inflammation in the front of chamber of eye. In eye with significant bleeding the interior of the eye may not be visualized. There are numerous potential intraocular causes for hyphema, such as blunt or penetrating trauma, inflammation, retinal detachment (Dubielzig *et al.* 2010), in this case trauma and inflammation also present. Whereas blunt trauma to the head seldom results in hyphema because the eyeball is protected by anterior portions of the bony orbit and orbital soft tissues, severe blunt trauma to the anterior orbital rim or per orbital soft tissues and eyeball may cause hemorrhage in the anterior chamber (Komáromy *et al.* 1999) due to retinal detachment or tear of the ciliary body (Book *et al.* 2008). This case also suffered with trauma presented hyphema after being hit by a motor cycle and suffering ocular proptosis. The use of antibiotics and steroids helped to reduce periorbital swelling and secondary infection.

### References

- [1] Book B.P., Van der Woerd A. & Wilkie D.A. 2008. Ultrasonographic abnormalities in eyes with traumatic hyphema obscuring intraocular structures: 33 cases (1991-2002). *J. Vet. Emerg. Crit. Care* 18:383-387.
- [2] Dubielzig R.R., Ketring K.L., McLellan G.J. & Albert D.M. (2010.) Non-surgical trauma In: *Veterinary Ocular Pathology: a comparative review*. Ibid. (Eds), Elsevier, Edinburgh., p.81-114.
- [3] Gilger B.C, *et al.* (1995) Traumatic ocular proptoses in dogs and cats: 84cases (1980-1993). *J Am Vet Med Assoc.*; 206(8): 1186-1190.
- [4] Komáromy A.M., Ramsey D.T., Brooks D.E., Ramsey C.C., Kallberg M.E. & Andrew S.E. 1999.Hyphema. I. Pathophysiologic considerations. *Compend. Contin. Educ. Vet.* 21:1064-1069.
- [5] Mandell, D.C. (2005). Ophthalmic emergencies. *Clinical Tech. Sm. Anim. Pract.* 15:94-100.
- [6] Martins T.B. & Barros C.S.L. 2015. Red eyes in the necropsy floor: twenty cases of hyphema in dogs and cats. *Pesquisa Veterinária Brasileira* 35(1):55-61. Programmede Pós-Graduaçãoem Medicina Veterinária, Universidade Federal de Santa Maria, Camobi, Santa Maria, RS 97105-900,
- [7] Ofri, R. (2008). Differential diagnosis and treatment of blindness. *Scientific Proceedings: Companion Animals Programme. European Veterinary Conference, Voorjaarsdagen. Netherlands.* pp. 1.



**Fig 1** Traumatic proptosis of cat



**Fig 2** Proptosis eye after tarsorrhaphy